

P53 Immunoeexpression in Laryngeal Squamous Cell Carcinoma

LILIANA CERCELARU¹, A.E. STEPAN¹, C. MĂRGĂRITESCU¹,
A. OSMAN², IONELIA-CARMEN POPA¹,
CRISTIANA EUGENIA SIMIONESCU¹, OTILIA MĂRGĂRITESCU³

¹Department of Pathology, University of Medicine and Pharmacy of Craiova, Romania

²Department of Anatomy, University of Medicine and Pharmacy of Craiova, Romania

³Department of Neurosurgery, University of Medicine and Pharmacy of Craiova, Romania

ABSTRACT: p53 is a marker described in the premalignant lesions with a high risk of malignant transformation for laryngeal cancer. It is a tumor suppressor gene that during the cancer gains also oncogenic activity. We aimed to study the p53 immunoeexpression in 38 cases of laryngeal squamous cell carcinomas and the relation with the clinicopathological aspects. We obtained variable p53 expression regarding the differentiation degree and tumor stage. The higher p53 immunotaining values were observed in high grade and advanced stages lesions. P53 may be useful in identifying aggressive laryngeal squamous carcinomas, a useful aspect for better stratification of patients for therapy.

KEYWORDS: p53, laryngeal squamous cell carcinoma

Introduction

Larynx is one of the most common site of cancer and represents 2.4% of all cancers [1]. It is a disease with a huge impact on communication and survival. More than 50% of the cases are diagnosed in advanced stages where survival rate is between 10-40% compared to the early stages where the rate is over 60% [2,3].

Modifications of normal p53 gene are frequent events described in the appearance of cancer, including laryngeal cancers [4]. The p53 gene, located on chromosome 17p13.1 encodes the protein involved in many physiological processes, like apoptosis or inflammation [5-6]. P53 has been described as having a dual role, both cell cycle and apoptosis [7].

P53 has been linked to premalignant lesions, the ones known to have the potential to become malignant and, in cancer, in the cases with a high risk of a bad response to therapy [8-10].

In the present study, we aimed p53 expression in the laryngeal squamous cell carcinomas and the correlation with the clinicopathological parameters.

Material and methods

The study included 38 cases of laryngeal squamous cell carcinomas selected during a period of three years from the cases hospitalized and operated in Otolaryngology Clinics of the Emergency County Hospital of Craiova and diagnosed in the Pathology Department. The

surgical pieces were fixed in 10% buffered formalin, processed by the usual technique with paraffin embedding and Hematoxylin-Eosin (HE) staining. Classification and staging have been made in accordance to World Health Organization (WHO) recommendation [11].

The parameters analyzed in the present study were represented by age, gender, histological grade, depth of invasion (pT), lymph node metastasis (pN) and tumor stage. In this study the distant metastasis were absent. The immunoreactions were performed on serial sections, using the monoclonal mouse antihuman p53 antibody (Dako, Redox, Romania), clone DO-7, in dilution 1:50 and antigen retrieval represented by microwaving in Tris-EDTA pH 9 buffer for 20 minutes.

Immunohistochemical reactions were obtained using LSAB2-HRP (Labeled Streptavidin Biotin-Horseradish Peroxidase) amplification system (DAKO, Redox, Bucharest, code K0675) and for the signal visualization 3,3'-diaminobenzidine tetrahydrochloride (DAB, DAKO, code 3467) as chromogen. To validate the obtained reactions, we use external negative (by omitting the primary antibody) and positive (breast cancer) controls.

A semiquantitative quantification based on a scoring system was used. It was taken into account the reactions intensity and the number of labeled cells. The number of labeled cells was assessed on microscopic field of 200x, and represents an average value of positive cells reported on the total number of cells of the entire specimen. The intensity was scored as mild (score 1), moderate (score 2) and intense

(score 3). The number of labeled cells was considered as score 1 for <25% marked cells, score 2 for >26-50% marked cells, and score 3 for 51-74% marked cells and score 4 for >75% marked cells. By the multiplying of the scores for intensity and labeled cells it was obtained final staining score, with values between 1 and 12. For the statistical analysis, the values between 1 and 4 were considered low and the values between 6 and 12 were high.

Statistical analysis was performed using chi-square tests within Statistical Package for the Social Sciences (SPSS) 20 software and p-values <0.05 were considered significant. For the image acquisition were used Nikon Eclipse E600 microscope and Lucia 5 software. The study was approved by the local ethical committee (no.173/11.09.2017), and written informed consent was obtained from all the patients.

Results

Most of the cases included in the present study were present in males aged over 50 years. Regarding the differentiation degree, the higher number of cases were moderate squamous cell carcinomas (22 cases) and in 26 cases there were present no lymph node metastases (pN0). Advanced stages, with 19 cases for the stage III and 10 cases for the stage IV were diagnosed in a superior number of cases compared to the early (I and II) stages (Table 1).

Table 1. Cases distribution according to the investigated clinicopathological parameters

Parameter	Variable
Age	<50 years old=2 >50 years old=36
Gender	Females=3; Males=35
Differentiation degree	WD*=7; MD*=22; PD*=9
Depth of invasion (pT)	T1=3; T2=9; T3=22; T4=4
Lymph node metastasis (pN)	N0=26; N1=4; N2=8
pTNM stage	I=3; II=6; III=19; IV=10

*WD: well differentiated; MD: moderate differentiated; PD: poorly differentiated

Nuclear marked cells were considerate to be positive, in 52.2% of the squamous cell carcinoma cases. We noted a variability regarding the percentage of the marked cells but also the reactions intensities depending on the degree of differentiation and the pTNM stages.

For the well differentiated cases we found a mean value of 23.1±4.2, variable intensity and a mean score of 3.1 (Fig.1, Table 2). For the

moderate differentiated squamous cell carcinomas, the average percentage was 52.4±11.8, also variable intensity and the mean score of 6.5 (Fig.2, Table 2). The higher values were present in the poorly differentiated cases where we obtained the mean value of 75.7±21.1, variable intensity and the mean score of 6.5 (Fig.3, Table 2).

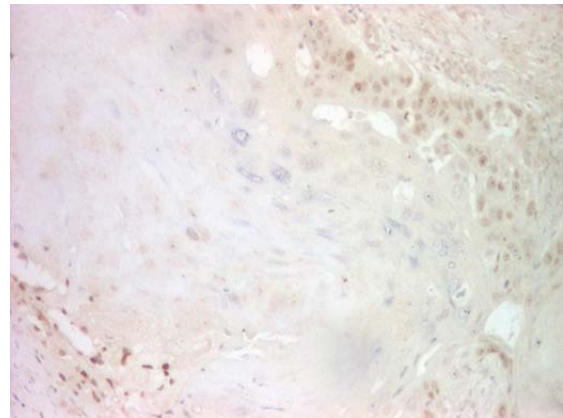


Fig.1. Well differentiated laryngeal squamous cell carcinoma, p53 immunostaining, x100

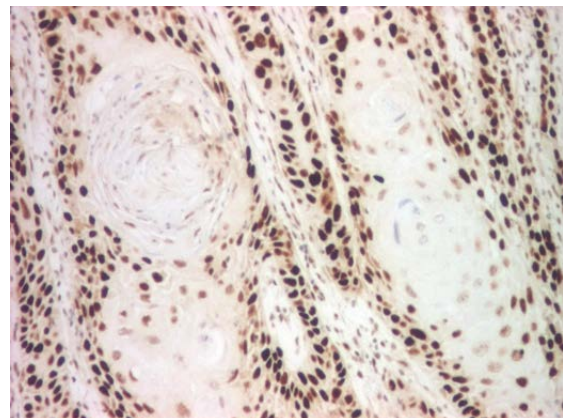


Fig.2. Moderate differentiated laryngeal squamous cell carcinoma, p53 immunostaining, x100

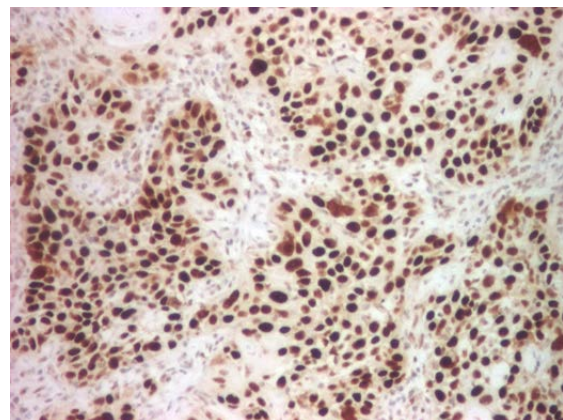


Fig.3. Poorly differentiated laryngeal squamous cell carcinoma, p53 immunostaining, x100

Analyzing the percentages for the pTNM stages we found: for stage I the average value of marked cells of 58.6±34.9, moderate/low intensity and a mean score of 5.3, for stage II the mean value was 44.2±23.08, also a variable

intensity and the mean score of 3.6. The advanced stages, respectively III and IV, presented the higher mean values of 53±19.1 and 54.9±24.1, moderate/high intensities and the mean scores of 7 and 5.5 (Table 2).

Table 2. Immunostaining scores in relation with clinicopathological parameters

Parameters	No. cases	p53		P value
		% cells ± SD*	Mean score	
Age	<50	2	60,5±36,4	0,032
	>50	36	52,1±21,4	
Gender	F	3	84,8±12,2	0,220
	M	35	49,8±20,1	
Differentiation degree	WD*	7	23,1±4,2	0,030
	MD*	22	52,4±11,8	
	PD*	9	75,7±21,1	
Depth of invasion (pT)	T1	3	58,6±34,9	0,183
	T2	9	55,1±26,3	
	T3	22	52,9±18,9	
	T4	4	40,5±20,2	
Lymph node metastasis (pN)	N0	26	49,6±20,1	0,212
	N1	4	53,4±32,4	
	N2	8	61,6±21,8	
pTNM stage	I	3	58,6±34,9	0,031
	II	6	44,2±23,08	
	III	19	53±19,1	
	IV	10	54,9±24,1	

SD=Standard deviation, F:Female, M: Male, WD=Well differentiated, MD=Moderate differentiated, PD=Poorly differentiated

After the examination of the parameters included in the study we obtained significant increased p53 values in poorly differentiated carcinomas compared with moderate and well differentiated ones (p=0.030, chi square test) (Fig.4). We have also noted a significant association between the marker and the pTNM stages (p=0.031), the higher expression being present in the advanced stages compared to the early stages of lesions (Fig.5).

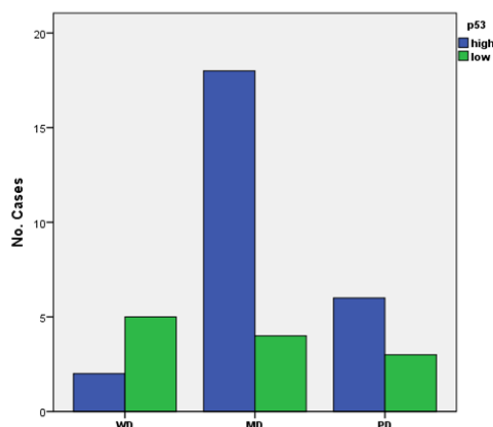


Fig.4. Cases distribution according to the scores of p53 and the differentiation degree

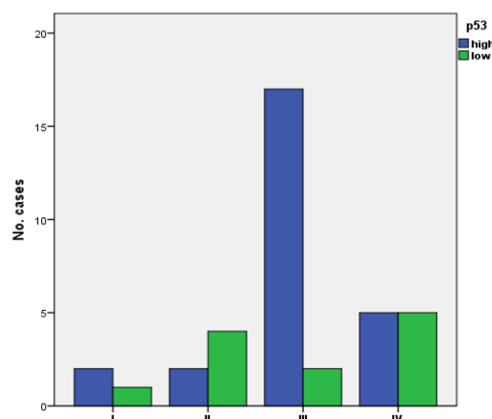


Fig.5. Cases distribution according to the scores of p53 and the pTNM stages

Discussion

The apoptotic process is considerate to be responsible for the destruction of abnormal cells during a physiological phenomenon. In some circumstances, the mechanisms are disturbed and this capacity of destroying abnormal cells is lost [12]. This situation is encountered both spontaneously as well as after treatment [13].

The appearance of cancer is a process in which are involved genetic mutations, like activation of oncogenes and inactivation of tumor suppressors. p53 represents such a

mutated gene, more exactly a suppressor gene, described in laryngeal squamous cell carcinomas as well [14-15]. The inactivation of this gene is frequently associated to cancer, as being a hallmark of it [16]. Growth or survival of tumor cells are only some of the advantages gained after the inactivation of this tumor suppressor [16]. The mutations are described as present in up to almost 70% of the head and neck cancers [2]. Their presence is related to an unfavorable prognosis [2]. This marker is described in the early stages of cancer next to the inactivation of p16, and the accumulation and not the order of these alternation are involved in the progression process [17]. In addition, p53 after inactivation has been shown to obtain oncogenic activity compared to other suppressor genes [4,10].

In the present study, we analyzed p53 immunoexpression in 38 cases of squamous cell carcinomas. We have found a positive nuclear expression in 52.5% of the cases. Both the percentage and the intensity of the positive reaction varied with the differentiation degree and the pTNM stage. The higher values were noticed in the poorly differentiated cases compared to the well differentiated ones. For the laryngeal squamous cell carcinomas, the literature, describes variable values of p53 expression between 22-64.8% of the cases [7,18-19]. Searching through literature, studies indicate significant association between p53 and tumor location, pTNM stage and lymph node metastasis [19]. According to our study, significant differences were noticed in p53 relation to the degree of differentiation and pTNM stages, the reaction being significantly superior in the moderate and poorly differentiated cases compared to the well differentiated ones.

Overexpression of p53 has been reported as an indicator of poor prognosis, with a poor disease-free survival and also overall survival for patients with squamous cell carcinomas [2]. The literature describes a relation between the marker overexpression and the prognosis for the laryngeal location, a relation that is stronger than in any other location of the cancer [4].

Treatment outcome after radio- or chemotherapy it is influenced by the mutations of p53 [20]. Different studies demonstrated the relation between the aberrant p53 expression and the higher risk of recurrence and the shorter free-disease period after radiotherapy [9-10].

Conclusions

For this study, we obtained higher expression of p53 in the high grade and advanced stages of laryngeal squamous cell carcinomas. Statistical analysis revealed significant increased p53 values in poorly differentiated carcinomas compared with moderate and well differentiated ones. P53 may be useful in identifying aggressive laryngeal squamous carcinomas, a useful aspect for better stratification of patients for therapy.

References

1. Zhang SY, Lu ZM, Luo XN, Chen LS, Ge PJ, Song XH, Chen SH, Wu YL. Retrospective analysis of prognostic factors in 205 patients with laryngeal squamous cell carcinoma who underwent surgical treatment. *PLoS One*; 2013; 8(4):e60157.
2. Thomas GR, Nadiminti H, Regalado J. Molecular predictors of clinical outcome in patients with head and neck squamous cell carcinoma. *Int J ExpPathol*; 2005; 86(6):347-363.
3. Markou K, Christoforidou A, Karasmanis I, Tsiropoulos G, Triaridis S, Constantinidis I, Vital V, Nikolaou A. Laryngeal cancer: epidemiological data from Northern Greece and review of the literature. *Hippokratia*; 2013; 17(4):313-318.
4. Peltonen JK, Helppi HM, Pääkkö P, Turpeenniemi-Hujanen T, Vähäkangas KH. p53 in head and neck cancer: functional consequences and environmental implication of tp53 mutations. *Head Neck Oncol*; 2010; 2:36.
5. Bensaad K, Vousden KH. p53: new roles in metabolism. *Trends Cell Biol*; 2007; 17(6):286-291.
6. Hussain SP, Harris CC. p53 biological network: at the crossroads of the cellular-stress response pathway and molecular carcinogenesis. *J Nippon Med Sch*; 2006; 73(2):54-64.
7. Şimşek G, Han Ü, Önal B, Köybaşıoğlu FF, Akin I, Dağlı M. Expression of cyclin D1, p21, p21, bcl-2, and p53 in laryngeal squamous cell carcinoma and an investigation of the correlation with conventional prognostic factors. *Turk J Med Sci*; 2013; 43:27-32.
8. Anghelina F, Ioniță E, Popescu CF, Ioniță I, Mogoantă C, Ciolofan S, Mogoantă L. Clinical, morphological and immunohistochemical aspects in laryngeal premalignant lesions. *Rom J Morphol Embryol*; 2006; 47(2):169-174.
9. Kastan MB, Onyekwere O, Sidransky D, Vogelstein B, Craig RW. Participation of p53 protein in the cellular response to DNA damage. *Cancer Res*; 1991; 51(23 Pt 1):6304-6311.
10. Koch WM, Brennan JA, Zahurak M, Goodman SN, Westra WH, Schwab D, Yoo GH, Lee DJ, Forastiere AA, Sidransky D. p53 mutation and locoregional treatment failure in head and neck squamous cell carcinoma. *J Natl Cancer Inst*; 1996; 88(21):1580-1586.
11. Barnes L, Eveson JW, Reichart P, Sidransky D. Hypopharynx, larynx and trachea. In: Kleihues P, Sobin LH (Eds): *World Health Organization Classification of Tumours Pathology and Genetics of Head and Neck Tumours*, 2005, IARC Press, Lyon, 107-162.
12. Sarkar FH, Li Y. Markers of apoptosis. *Methods Mol Med*; 2006; 120:147-160.

13. Holdenrieder S, Stieber P. Apoptotic markers in cancer. Clin Biochem; 2004; 37(7):605-617.
14. Garozzo A, Cutrona D, Palmeri S, Maiolino L, Puzzo L, Allegra E. The role of p53 tumor suppressor gene as prognostic factor in laryngeal squamous cell carcinoma. Acta Otorhinolaryngol Ital; 1999; 19(6):342-347.
15. Gorgoulis V, Rassidakis G, Karameris A, Giatromanolaki A, Barbatis C, Kittas C. Expression of p53 protein in laryngeal squamous cell carcinoma and dysplasia: possible correlation with human papillomavirus infection and clinicopathological findings. Virchows Arch; 1994; 425(5):481-489.
16. Rivlin N, Brosh R, Oren M, Rotter V. Mutations in the p53 Tumor Suppressor Gene: Important Milestones at the Various Steps of Tumorigenesis. Genes Cancer; 2011; 2(4):466-474.
17. Califano J, van der Riet P, Westra W, Nawroz H, Clayman G, Piantadosi S, Corio R, Lee D, Greenberg B, Koch W, Sidransky D. Genetic progression model for head and neck cancer: implication for field cancerization. Cancer Res; 1996; 56(11):2488-2492.
18. Shin DM, Lee JS, Lippman SM, Lee JJ, Tu ZN, Choi G, Heyne K, Shin HJ, Ro JY, Goepfert H, Hong WK, Hittelman WN. p53 expressions: predicting recurrence and second primary tumors in head and neck squamous cell carcinoma. J Natl Cancer Inst; 1996; 88(8):519-529.
19. Ashraf MJ, Maghbul M, Azarpira N, Khademi B. Expression of Ki67 and P53 in primary squamous cell carcinoma of the larynx. Indian J Pathol Microbiol; 2010; 53(4):661-665.
20. Bush JA, Li G. Cancer chemoresistance: the relationship between p53 and multidrug transporters. Int J Cancer; 2002; 98(3):323-330.

*Corresponding Author: A.E. Stepan, Department of Pathology,
University of Medicine and Pharmacy of Craiova, 66 I May Avenue, 200628 Craiova, Romania,
e-mail: astepan76@yahoo.com*