

Case Report

Study on Crown - Root Reconstruction and Functional Occlusion

M.R. POPESCU¹, L.P.DRAGOMIR¹, MĂDĂLINA OLTEANU²

¹Department of Prosthetics and Oclusology, Faculty of Dental Medicine,
University of Medicine and Pharmacy of Craiova

²Department of Pedodontics,
Faculty of Dental Medicine, University of Medicine and Pharmacy of Craiova

ABSTRACT: The direction of action of masticatory pressure on the teeth depends on the position of the teeth, their morphology and position of the mandible to the maxillary, central or eccentric. The closer is the chewing withstanding carried out in a direction to the axis of the tooth; the greater is the periodontal protection. This study highlights various methods of reconstruction crown-root and sustainability criteria through the eyes of functional occlusion.

KEYWORDS: crown-root reconstruction, masticatory force, functional occlusion.

Introduction

The extensive coronary destruction determine events from all dental mechanism components, but the most visible and the ones the dentist is interested in are the ones from the occlusal level. The extensive coronary lesions give rise to an occlusal-articular functional imbalance simple or complex, depending on the number of affected units periodontal dental and on the intensity of pathophysiological overload of the outstanding structure [1,2]. The latter can have subliminal intensities, when the patient does not realize the existence of these requests, so there are no subjective evidences, but by adapting tissues to a pathological state, there appear objective signs that make possible to detect the installed imbalance, or supraliminar when besides the objective signs, there are also subjective signs indicating the patient the disease presence. The management of treatment stages is determined by the dental unit involved, its arch position, its status in terms of coronal damage, tooth vitality and not least the presence of periodontal pathology [3,4].

Material and method

The study was conducted in the Clinic for Fixed Dental Prosthetics-Occlusion on a number of 38 patients with various coronary destructions. It should be noted that irrespective of the method of treatment, the occlusal equilibration stage was the one which allowed drawing conclusions regarding the reconstitution viability. As crown-root reconstruction techniques, was chosen the

reconstitution by the addition method using light-cured cements composite combined with prefabricated cemented pins or screwed and substitution method with crown-root dispenser and crown molding physiognomy.

Results

Patient B.A., aged 28 years presented to the level 2.6. surface and deep carious lesion, this affects coronary walls: mesial, occlusal and distal. After retro alveolar dental radiography, I noticed that the dental roots have an optimal direction and length for using root pins. We mention that the tooth was devitalized, with endodontic treatment and root fillings correctly executed. Taking into account the particularity of this clinical case, we considered that to restore coronary morphology, the most appropriate are light-cured composite cements and to reduce the risk of root fracture and provide additional retention of the composite material, we used prefabricate pins.

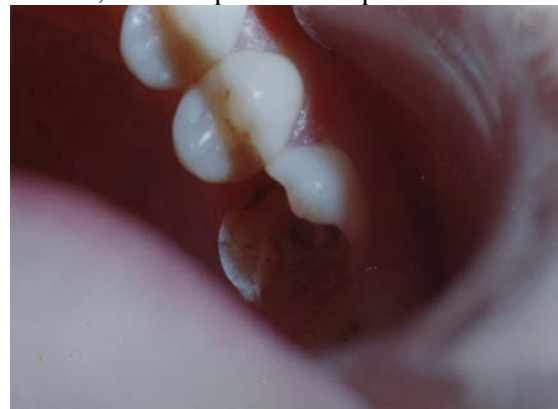

Fig.1. Destructive crown-original aspect

Permeability of root canal is performed with Kerr needles of various sizes. Kerr needles are used progressive without penetrate too far and to not create false ways. The use in the next step of the Beuttelrock drills should be carefully done; very important in this stage is keeping apical tightness.

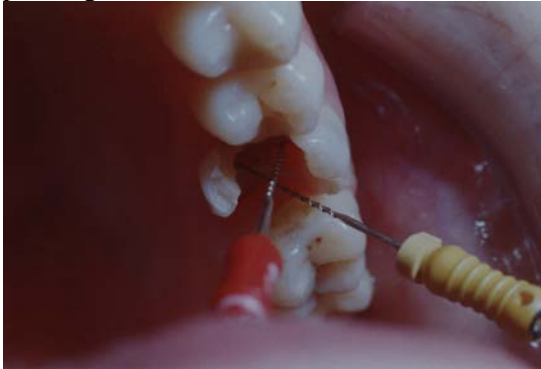

Fig. 2. Root canal instrumentation by permeability using Kerr needles

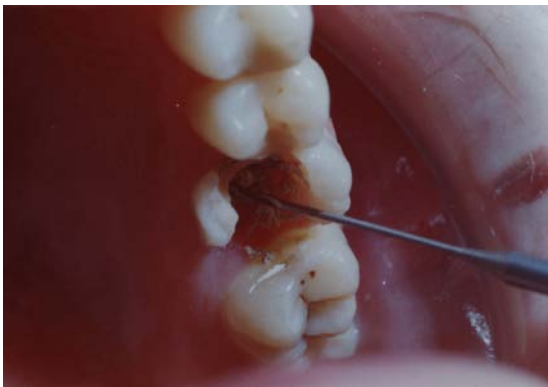


Fig. 3. The execution of root sanctuaries through instrumentation with Beuttelrock dental drills

After root canal preparation it followed the screwing and in the same time the cementation with phosphate cement of prefabricated pins. We mention that the choice of these is made after a preliminary determination of root diameter sanctuary.

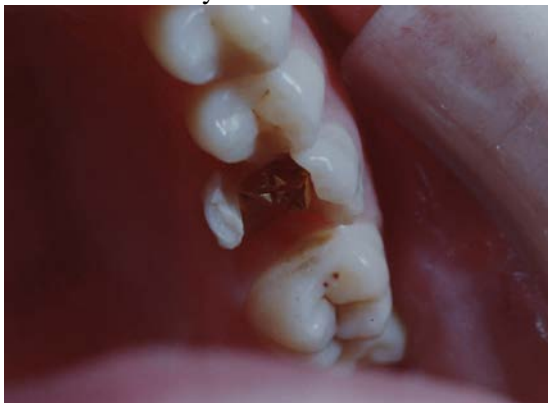

Fig. 4. Application of the prefabricated pins at root canals level

The next step involves coronal reconstitution using composite. Its use is made after aesthetic evaluation, while respecting the characteristic morphology of maxillary second molar. Application of the composite material is made in layers by addition method, very important being the polymerization after each applied layer. This curing is made in different angles, so that the curing is made in surface and depth.

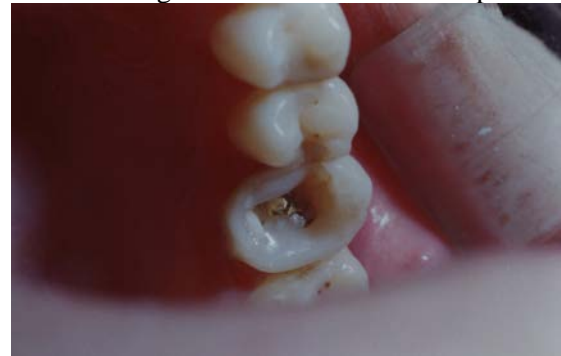

Fig. 5. Coronal reconstruction through addition method

The association with occlusion rebalancing is mandatory knowing that any changes in occlusal relief may allow the occurrence of premature contacts and occlusal interferences.

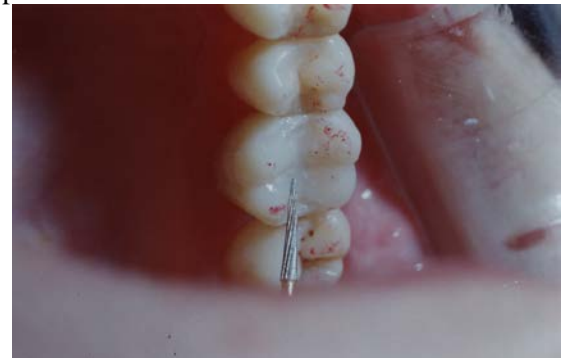

Fig. 6. Occlusion equilibration

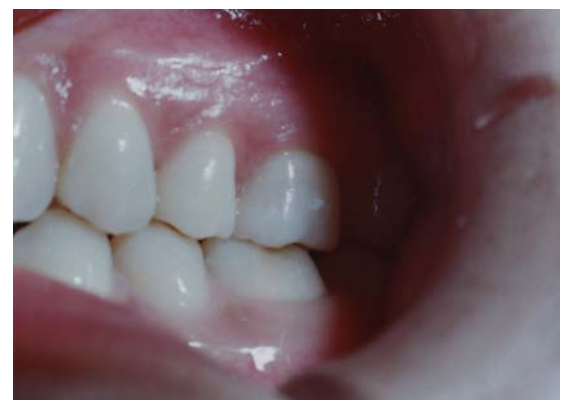

Fig.7 Overview after coronary reconstruction and occlusion equilibration

Another version of coronal reconstruction is the one in which the treatment is essentially

prosthetic. Below we present the clinical case of a patient who presents large coronary destructions at level of 15 and 25. The treatment follows the same logic as the previous regarding the execution of a root sanctuary. The option for the prosthetic treatment imposes the execution of devices crown-root, adapting and cementing them.

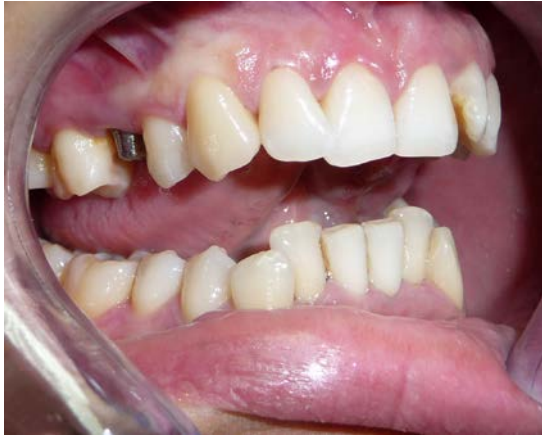

Fig. 8. Image after applying the crown-root device on 15

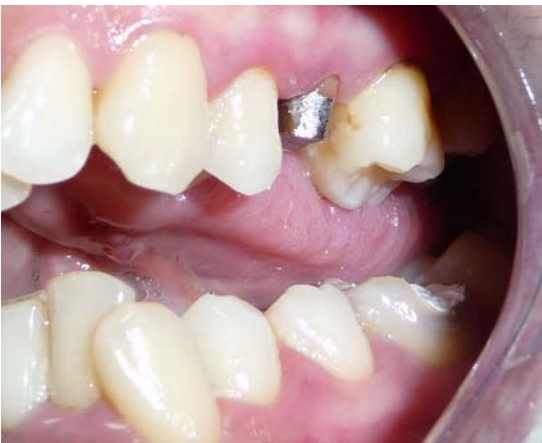

Fig. 9. Image after applying the DCR on 25

The next stage essentially prosthetic consists of fingerprinting the prosthetic field. As denture coverage there was opted for a unidentare metal-ceramic prosthesis totally physiognomycal. Clinical protocol and this case included the stage of occlusion rebalancing.

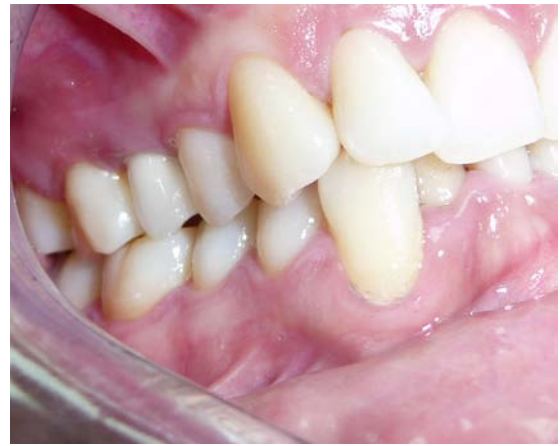

Fig. 10. Final clinical aspect-right hemiarcade

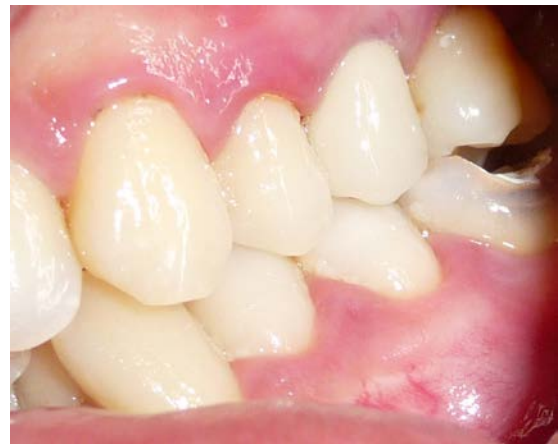

Fig. 11. Final clinical aspect-left hemiarcade

Discussions

The tooth can be considered a leverage of first degree in which the strength arm is the crown, the resistance arm is the root, and the neck represents the support.

The stability is even greater as root - crown ratio is higher, the physiological ratio being 2/1.

The pathological changes of this report accompanied by moving the fulcrum towards the apex, causes lengthening of the strength arm and shortening of the resistance arm and the tooth behavior as a leverage of second degree, being created unfavorable conditions static-dynamic for the tooth [5].

Lower front teeth get pressure in axis, while the higher take pressures on oral face and oblique to their implantation [6].

That is why it has imposed a morphological adaptation of upper incisors to increase their size mesial-distal coronal and root. Thus, the masticatory pressures are transmitted on a greater bone area.

At the level of lateral teeth of active part, the masticatory forces break down on cuspals lopes in a vertical component which is transmitted in

the long axis of the teeth and a horizontal components of low intensity [7,8]. Canceling the harmful effect of the horizontal components is achieved by two mechanisms:

- a) transmission of these forces from the level of active part teeth of the wide arches level through contact points;
- b) transforming the horizontal components in pressure forces on the level of the dento-alveolar ligament forces which act on the paradontium microzonese qually and opposite canceling each other.

The loss of occlusion ratio with antagonist has negative consequences especially on the other parts of masticatory apparatus [9]. One of the negative effects is the lack of physiological stimuli of periodontal receptors of the antagonist integrity tooth [10].

These stimulus are acting in self-defense and self-stimulation of the good tooth paradontium.

The absence of this stimulus triggers the good tooth movement in a vertical direction. In this case the migrated tooth establishes another occlusal contact, but a pathological one.

Through this vertical migration called passive eruption, the occlusal side or incisal migrated tooth edge goes beyond the occlusal level.

This overtaking of occlusal level determines, after different mandibular movements, some occlusal interferences or a premature contact. This situation can linger to rebuild dental units also. One can say that occlusal rebalance represents a crucial step, mandatory to run a balanced homeostasis at masticator level.

Conclusions

Superior palatine cusps and vestibular inferior have a very important role both

inocclusion maintaining and in mastication which defined them as active cusps, occlusal support cusps.

Occlusal arrest is done by active cusps contact with rising edge and fosses having as an effect stabilization of maxillary on the jaw.

References

1. Mc Neill C.-Occlusion: what it is and what it is not. J Calif Dent Assoc 28(10):748-58;2000.
2. Millstein P., Maya A.-An evaluation of occlusal contact marking indicators. A descriptive quantitative method. J. Am. Dent. Ass., The 132(9):1280-6; quiz 1319;2001.
3. Dawson PE. Evaluation, Diagnosis and Treatment of Occlusal Problems. 2nd ed. St. Louis, Mo: CV Mosbz.1989.
4. Clark G.T.-Interocclusal Appliance Therapy, in: Mohl, N.D., Zarb, G.A., Carlsson, G.E., Rugh, J.D.: Textbook of Occlusion, Chicago, Quintessence; 1988.
5. M.R. Popescu, Petra Surlin, Mihaela Raescu, C. Daguci, L. Dragomir; Study regarding the role of occlusal examination in setting aesthetic benchmarks- Revista Romana De Stomatologie, VOL.LVII,NO.1, 2011.
6. Burlui V.-Gnatologie, Editura Apollonia, Iasi, 137-242,248-264; 2000.
7. Burlui V.-Malrelerlatiile cranio-mandibulare, Editura Apollonia, Iasi, 185-241,311-340; 2002.
8. M. R. Popescu, C. Daguci, L.P. Dragomir, Occlusal Screening as Basis for the Integration of Conjunct Gnato-Prosthetic Devices; Current Health Sciences Journal, Vol. 36, No. 3, 2010.
9. Butler J.H.-Occlusal adjustment. Dent. Dig.(10):422-6;1970
10. Christensen L., Rassouli N.-Experimental occlusal interferences. Part IV. Mandibular rotations induced by a pliable interference. J. Oral. Rehab, 22(11): 835-44; 1995 Nov.
11. M. R. Popescu, L. Chirigiu, L.P. Dragomir; Dental Morphology as an Aesthetic Reference in Prosthetic Reconstruction of Lateral Maxillary Areas-M.; Current Health Sciences Journal, Vol. 39, No. 3, 2013 July September