

Systemic Atheromatosis Influence on Retinal Vascular Disease

A.ȘTEFĂNESCU¹, T.SAS¹, C.BĂȚĂIOSU²

¹University of Medicine and Pharmacy of Craiova

²County Emergency University Hospital, Craiova

ABSTRACT: Clinical study on a group of 48 patients over 3 months: 27 patients were recruited from ophthalmology and 21 recruited from cardiology, 25 % of these patients coming for routine check. Patients were investigated by ophthalmic, cardiologic examination, imaging and laboratory tests. The study demonstrated the need for interdisciplinary consultation for patients with vascular complaints in carotid territory and a close correlation between the vascular pathology and ophthalmology at this level.

KEYWORDS: systemic atheromatosis, carotid atherosclerosis, retinal vascular diseases

Introduction

Carotid atherosclerosis is the pathological thickening of carotid intima, usually in the form of plaque. Although plaque may remain stable for a long period of time, an unstable plaque rupture can lead to local formation of a thrombus that can embolize after at ocular or cerebral level [1].

Ophthalmologic examination in patients with systemic atheromatosis is very important because it allows assessment of vascular changes in the eye. Routine eye examination is recommended in all patients with vascular disease. The most common retinal diseases in the cardiovascular diseases: hypertensive retinopathy, retinal artery occlusion, retinal vein occlusion, ischemic optic neuropathy and diabetic retinopathy.

Retinal occlusions are severe eye disease leading to significant alterations to quality of life.

Ocular ischemic syndrome is a disease with a wide variety of signs and symptoms secondary to chronic ocular hypoperfusions, same side carotid stenosis in 90 %, leading to 50% reduction in ocular perfusion. Ocular ischemic syndrome may be associated with hypertension, diabetes, ischemic heart disease and cerebrovascular disease, hyperlipoproteinemia [2]. It occurs in people older than 65 years and not less than 50 years. The disease occurs in 80% unilaterally. The incidence of ocular ischemic syndrome is not known exactly, but is estimated at 7.5 cases per 1 million annually, according to a study by Sturrock and Mueller. It is believed that about 5 % of patients with hemodynamically significant carotid artery disease develop ocular ischemic syndrome.

The majority of central retinal artery occlusion is caused by thrombus formation at or just proximal to the lamina cribrosa. Atherosclerosis triggering event in most cases, although congenital central artery of retina, systemic blood clotting, and other conditions of the proximal pressure can also be present.

In only 20-25 % of cases are emboli, visible in the central retinal artery or one of its branches, suggesting that embolic cause is not frequent. Other indirect evidence against emboli as a common cause of central retinal artery obstruction is the probability of 40 % or less to find a definitive source on the assessment of systemic embolism and a low incidence (approximately 10%) confirmed the presence of cerebral emboli affected patients [3].

Inflammation in the form of vasculitis (e.g., chicken pox), optic neuritis, or orbital diseases (e.g., mucormycosis) may cause obstruction of the central retinal artery. Local trauma, which leads to direct damage to the optic nerve or blood vessels, can lead to obstruction of the central retinal artery. Arterial spasm occurs rarely retinal arterial obstruction. In addition, systemic coagulopathy may be associated with central occlusion and branch retinal artery.

The exact pathogenesis of central retinal vein occlusion remains obscure. Obstruction is the result of a thrombus in the central retinal vein at home or posterior lamina cribrosa. Arteriosclerosis central retinal artery, vein adjacent, causes changes in venous flow and then endothelial changes. An alternative theory is that the central retinal vein thrombosis is an end-stage phenomenon induced by a variety of primary lesions such as compression or inflammation of the optic nerve problems or orbital, structural abnormalities or changes in the lamina cribrosa.

Major causes of acute ischemia of the papilla are atherosclerosis in 75 % of cases, vasculitis, systemic vascular diseases, hematological diseases, diverse causes: cavernous sinus thrombosis, optic nerve head drusen, ocular contusions, and chronic glaucoma [4].

Material and method

It was studied a group of 48 patients examined within 3 months: 27 patients were recruited from ophthalmology and 21 recruited from cardiology, 25 % of patients coming for routine, knowing the family history cardiology, and existence of risk factors for cardiovascular and ophthalmological disease.

The ophthalmologic examination included: visual acuity with and without optical correction, biomicroscopy, autorefractometer, intraocular pressure and fundus examination and other examinations complementary optical coherence tomography in 37 patients and ocular ultrasound 5 patients.

Cardiologic examination was conducted as follows:

- Carotid Doppler ultrasound in 37 patients;
- Echocardiography in 37 patients;
- Electrocardiography in 38 patients;
- Test of effort in 7 patients;

Standard laboratory examination was performed on 48 patients, some of these patients have required additional laboratory analysis in the pathology they ha.

There are 48 sets of tests carried out in standard laboratory, consisting of:

- Complete blood count;
- Determination of total cholesterol;
- Dosage of HDL cholesterol;
- Dosage of LDL cholesterol;
- Dosage of triglycerides;
- Dosage of liver transaminases:
 - Alanine aminotransferase (ALT);
 - Aspartate aminotransferase (AST);
- Dosage of urea;
- Dosage of creatinine;
- Dosage of uric acid;
- Ionogram;
- Dosage of glucose;
- Erythrocyte sedimentation rate (ESR);

In 29 patients, it was requested and performed a set of complementary analysis consisting in:

- Dosage of fibrinogen;
- Determination of C-reactive protein;

In the other 14 patients was requested and performed a set of complementary analysis consisting in:

- Urinalysis ;
- Dosage of glycosylated hemoglobin;

6 patients have special laboratory tests were conducted consisting of:

- Dosage of protein S;
- Dosage of antithrombin III;
- Dosage of factor V;
- Lupus anticoagulant dosage;
- 3 patients were dosed troponins.

Discussion

• 9 patients with ophthalmic recruitment were presented either fundus examination, the diabetes doctor sent by either visual complaints in the underlying disease.

• identified three new cases of diabetes based on laboratory results that showed increases in blood glucose and glycosylated hemoglobin, fundus examination and OCT examination.

• 10 cases had carotid vascular changes, a case required medical treatment or surgery, the rest required medical treatment

• following laboratory results (urea, creatinine, high level of uric acid) 3 patients had suspected nephropathy which was advised nephrology consult.

• 2 patients developed a cataract within the pathology of diabetes. OCT examination ruled out other cause of decreased visual acuity (fundus changes if the underlying disease) and decided surgery : phacoemulsification with IOL implantation, improving the quality of life.

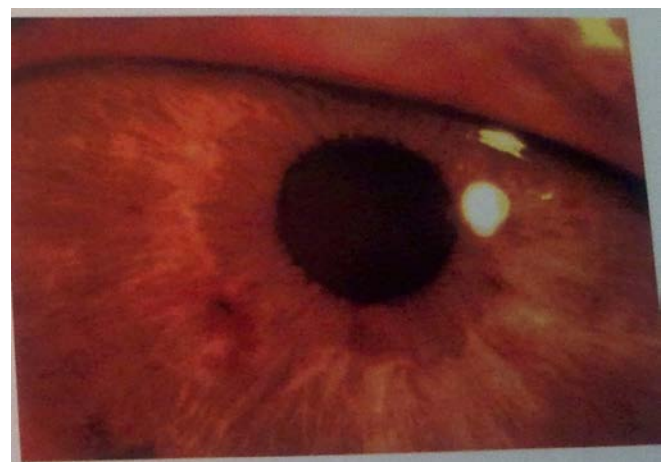


Fig.1. Left eye: anterior pole crystalline opacification

- In 2 patients by OCT examination were identified early lesions of diabetic disease, clinically non-disclosure.

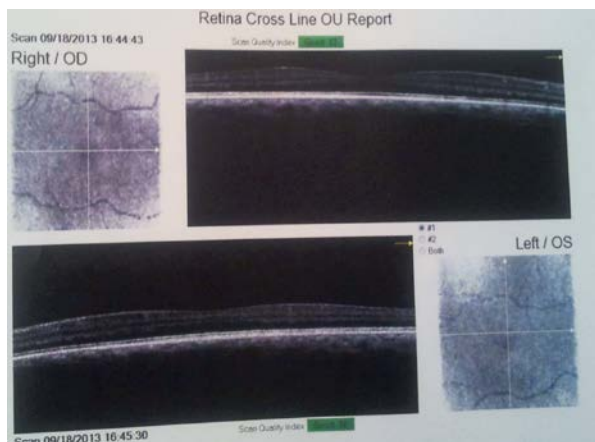


Fig.2.OCT macula right eye: drusen intraretinal

- 2 patients without visual complaints had signs of hypertensive angiopathy fundus examination.

- 5 patients with macular degeneration had neovascular membrane OCT examination, and 4 of them were present carotid Doppler changes requiring cardiovascular treatment. Ophthalmic therapeutic indication was intravitreal injection of Avastin. In all five laboratory results showed high levels of cholesterol and lipids.

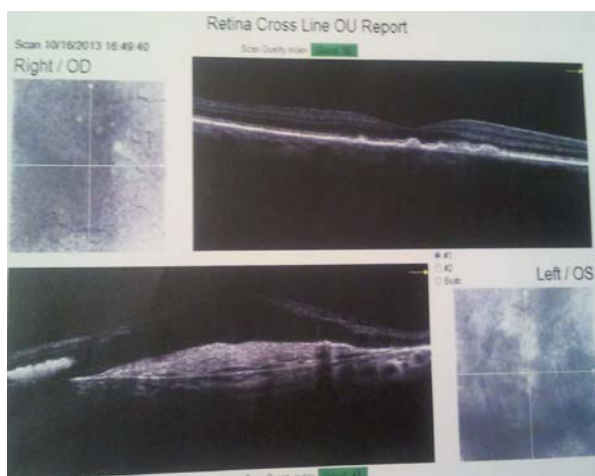


Fig.3.OCT macula right eye: neovascular membrane occult neovascular membrane; left eye: classic macular edema with disruption of retinal architecture.

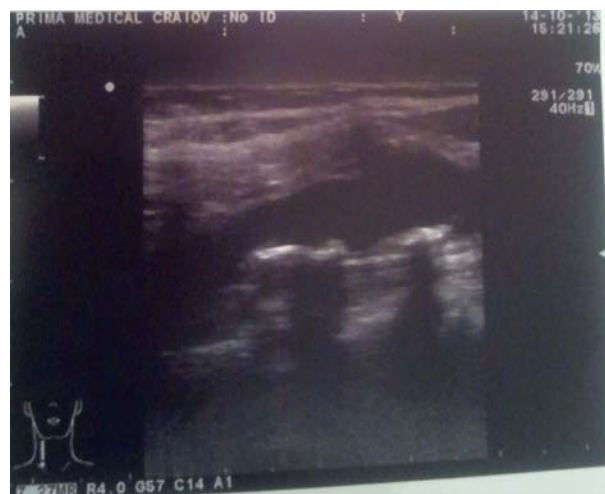

Fig.4.Carotid Doppler ACI heterogeneous plates with microcalcifications potentially embolism

- 2 patients at fundus examination were suspected of vascular disease of the optic nerve (posterior ischemic optic neuropathy). At one of her exam OCT showed cystoid macular edema with decreased visual acuity after cataract surgery.

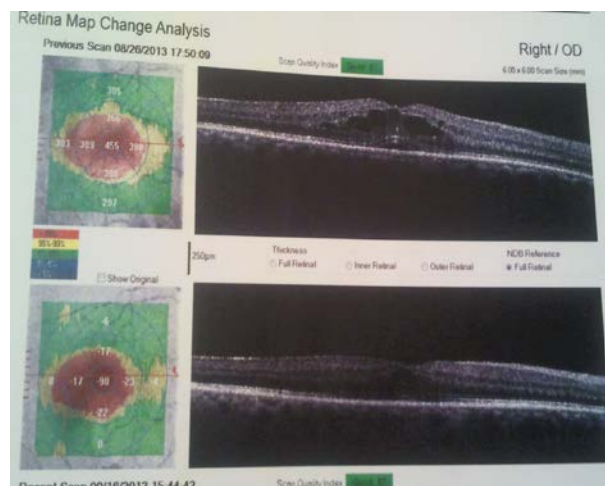


Fig.5.OCT macula: Right eye: cystoid macular edema

And a case presented amaurosis fugax instead OCT examination revealed no vascular lesions or other biological risk factors. Staying with the patient under observation.

- 1 patient with central retinal vein occlusion with normal lipid profile showed antithrombin III at a low level and severe Doppler vascular changes. In this patient was reassessed general treatment and anticoagulant treatment was initiated.

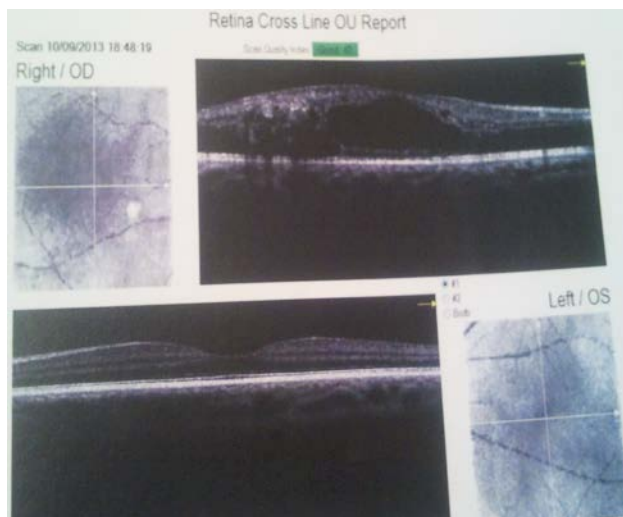

Fig.6.OCT macula: Right eye: macular edema with disorganization of retinal architecture

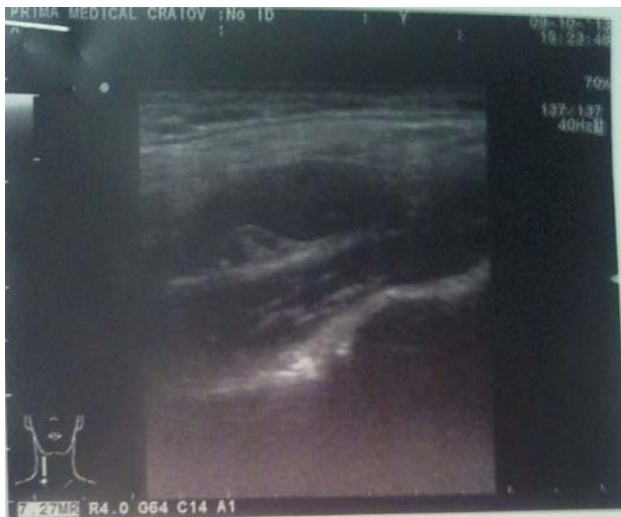

Fig.7.Carotid Doppler average left internal carotid artery stenosis, biologically active, high risk

For cardiology recruitment 2 cases showed decreased visual acuity represented by vascular complaints which actually turned out to be crystalline opacification - senile cataracts, OCT and ultrasound examination excluded other causes of vision loss. They recommended surgery by phacoemulsification with artificial lens implant.

A case of carotid vascular disease presented neovascular macular degeneration in the eye, recommended treatment was intravitreal injection of Avastin, which resulted in increased visual acuity.

Patients fully investigated in terms of cardiology showed the following:

- 90 % of patients were diagnosed with hypertension at high risk or very high when

being introduced or changed their antihypertensive treatment. These patients were informed of the need to maintain a blood pressure values below 130/80 mmHg constantly.

- Dyslipidemia was identified in 24 patients, statin therapy was introduced to bring LDL Cholesterol to a value of less than 70 mg / dL in very high -risk patients and less than 100 mg / dl in patients with high risk.

- At 15 patients was identified carotid atheromatosis, diagnosed by Doppler ultrasound in a patient being recommended surgery.

- 1 patient was diagnosed with peripheral arterial disease.

- Of 37 patients, 14 were diagnosed with effort or unstable angina and 11 were recommended to perform a stress test in the future, and even an angiography.

- Following the electrocardiogram were detected changes of most likely ischemic etiology at a number of 7 patients. Also were identified 2 patients who had suffered a previous myocardial infarction which was not documented. Also, we evaluated a patient which PTCA was performed per premium for acute myocardial infarction, the patient electrocardiogram not incurring changes in dynamics. In the 3 patients with stroke in this study were recommended to conduct a biennial effort test.

- At ultrasound, cardiac structural damage was diagnosed in 12 of the 37 patients, the main causes of the high blood pressure changes and myocardial ischemia.

- As a result of the 7 effort tests ECG, changes were detected only in 2 patients, in their case the investigation indicated invasive coronary angiography emergency.

Conclusions

Testing has shown a strong correlation between cardiovascular disease and ophthalmological disease of patients investigated, 70 % of patients recruited cardiology knowing they had eye pathology as a consequence of basic cardiovascular disease who were treated.

In 80 % of patients with retinal vascular disease was reviewed cardiology treatment so that to prevent repeat episode in the other eye and prevent cardiac or cerebral embolization.

Results of laboratory analysis have led in some cases to changes of the therapeutical behavior in terms of cardiology, being discovered additional risk factors for underlying disease: high levels of total cholesterol, HDL cholesterol, LDL cholesterol and triglycerides.

This study has shown the need for interdisciplinary consultation in patients with vascular complaints in the carotid territory and a close correlation between the vascular pathology and ophthalmology at this level.

Also diabetes is a disease that according to the results of investigations carried out has both

cardiovascular and ophthalmological significant negative impact.

References:

1. Ankur Thapar, Ieuan Harri Jenkins, Amrish Mehta, Alun Huw Davies - Diagnosis and management of carotid atherosclerosis
2. Matthew T.S. Tennant, Arunam Sivalingam, Gregory M.Fox, Gary C. Brown, Chapter 6.20 – Ocular Ischemic Syndrome, Yanoff&Duker, Ophthalmology 3rd Ed.
3. Jay S. Duker, Chapter 6.16 – Retinal Arterial Obstruction, Yanoff&Duker, Ophthalmology 3rd Ed.
4. Michael G. Morley, Jeffrey S. Heyer, Chapter 6.17 – Venous Obstructive Disease of the Retina, Yanoff&Duker, Ophthalmology 3rd ed.

Corresponding Author: Alin Ștefănescu, Department of Ophthalmology, University of Medicine and Pharmacy of Craiova, 2 Petru Rares St., Craiova, Romania