

## Diagnosis Particularities of Amyotrophic Lateral Sclerosis in an Elderly Patient

IULIA-RAHELA MARCU<sup>1</sup>, SIMONA PATRU<sup>1</sup>, A.C. BIGHEA<sup>1</sup>

<sup>1</sup>University of Medicine and Pharmacy of Craiova, Department of Physical Medicine and Rehabilitation

**ABSTRACT:** Amyotrophic lateral sclerosis (ALS) is a degenerative motor neuron disease (MND) which prognosis is poor. Early diagnosis permits to set up immediately adapted treatment. Available diagnostic criteria are based on the detection of both central and peripheral motor neuron injury in bulbar, cervical, thoracic and lumbar regions. Electrodiagnostic tests are key tools to identify peripheral motor neuron involvement. In the absence of a diagnostic biomarker of ALS, a careful clinical and neurophysiological work-up is essential to rule the differential diagnosis. The study presents the case of a 74 years-old woman who was diagnosed with ALS using clinical examination and electromyography.

**KEYWORDS:** amyotrophic lateral sclerosis, electromyography, diagnosis

### Introduction

Amyotrophic lateral sclerosis (ALS) is a degenerative disease of both central and peripheral motor neurons leading to gradual installation of motor deficits that may affect limbs, respiratory muscles, phonation and deglutition [1].

In much of the world, rates of ALS are unknown. In Europe, the disease affects about 2.2 people per 100.000 per year and in the United States, more than 5600 are diagnosed every year (over 1.87 per 100.000 per year) [2].

Its pathophysiology remains unclear and to date riluzole is the only one drug that may influence survival in ALS patients [3]. Nevertheless, other types of care, respiratory management or nutrition for example, multidisciplinary care may impact survival and quality of life in ALS [1]. Thus, reaching the diagnosis of ALS as early as possible remains a challenge for the clinician.

Discovery of clinical, biological, genetic, radiological and neurophysiological biomarkers of ALS is one of the main challenges of the scientific community [4,5,6]. At the moment, clinics and electrodiagnostic tests remain the ALS diagnosis based on El Escorial diagnostic criteria successively updated in Airlie House and Awaji-shima criteria [7,8,9].

Amyotrophic lateral sclerosis (ALS) criteria according to Airlie House criteria (El Escorial revised criteria) in light of Awaji-shima consensus recommendations. LMN: lower motor neuron. UMN: upper motor neuron.

ALS diagnosis requires: (1) the presence of evidence of LMN degeneration by clinical, electrophysiological or neuropathological examination, (2) presence of UMN degeneration

by clinical examination, (3) presence of progressive spread of symptoms or signs within a region or other regions, as determined by history, clinical examination or electrophysiological tests, and (4) absence of electrophysiological or pathological evidence of other disease processes that might explain the observed clinical and electrophysiological signs.

Diagnostic categories include: definite ALS (clinical or electrophysiological evidence by the presence of LMN as well as UMN signs in the bulbar region and at least two spinal regions or the presence of LMN and UMN signs in three spinal regions), probable ALS (clinical or electrophysiological evidence by LMN and UMN signs in at least two regions with some UMN signs necessarily rostral to the LMN signs, and possible ALS (clinical or electrophysiological signs of UMN or LMN dysfunction in only one region or UMN signs alone in two or more regions or LMN rostral to UMN signs).

We describe the case of a 74 year-old female patient with no known past medical history presented more than one year after the onset of bilateral upper and lower extremities weakness.

This study emphasizes the importance of electrodiagnostic studies associated with clinical features in making a diagnosis of ALS. At the same time, the diagnosis is essential for patient prognosis and management.

Written informed consent was obtained from the patient for publication of this case report and any accompanying images.

### Case report

The study presents the case of 74 years-old female patient, from the countryside, at the first presentation in a clinical hospital, who was

hospitalized on 19.06.2017 in the Physical Medicine and Rehabilitation Clinic of Emergency County Hospital Craiova for walking disorders, gripping impairment, fasciculations, and dizziness at rapid head movements, symptoms with onset one year and a half before presentation. The patient has not received any ambulatory treatment.

Physical examination revealed an underweight patient (height 1.61m, weight 46kg, BMI=17.7kg/m<sup>2</sup>), well oriented in time, place and person. Cranial nerve examination revealed no abnormalities except tongue fasciculations.

Standing position was possible, walking was possible with support, stepped, impossible on toes and heels, muscular strength for anterior tibial muscle=3/4 right/left, common extensor digitis=3 bilateral, hallux extensor muscle=2/3 right/left. The hands had osteoarthritic aspect, bilateral palmar aponeurosis, "simian hand" aspect with atrophy of thenar and hypothenar eminences and bilateral gripping impairment. Osteotonic reflexes were abolished, Babinski response was present. The patient had normal coordination of

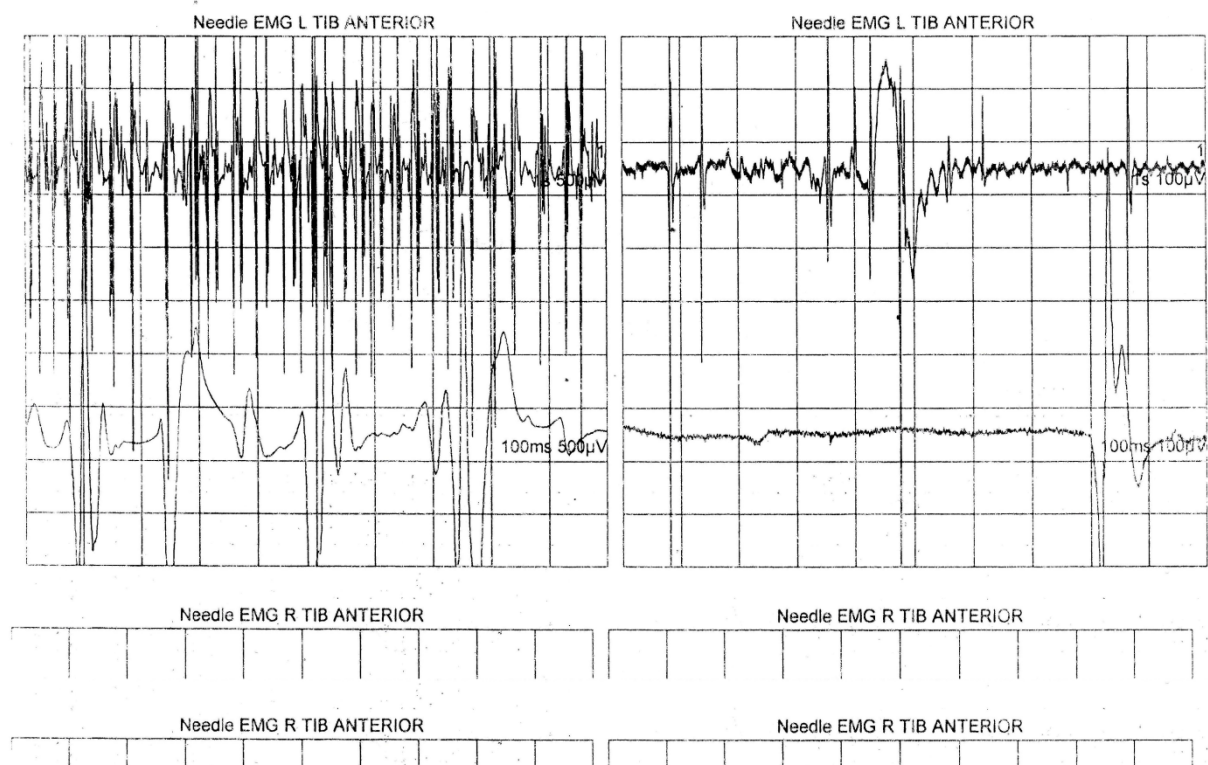
movement and there were no sensory abnormalities.

Lumbar spine X-rays showed accentuated vertebral osteoporosis and T-Score of DEXA examination was -2.8.

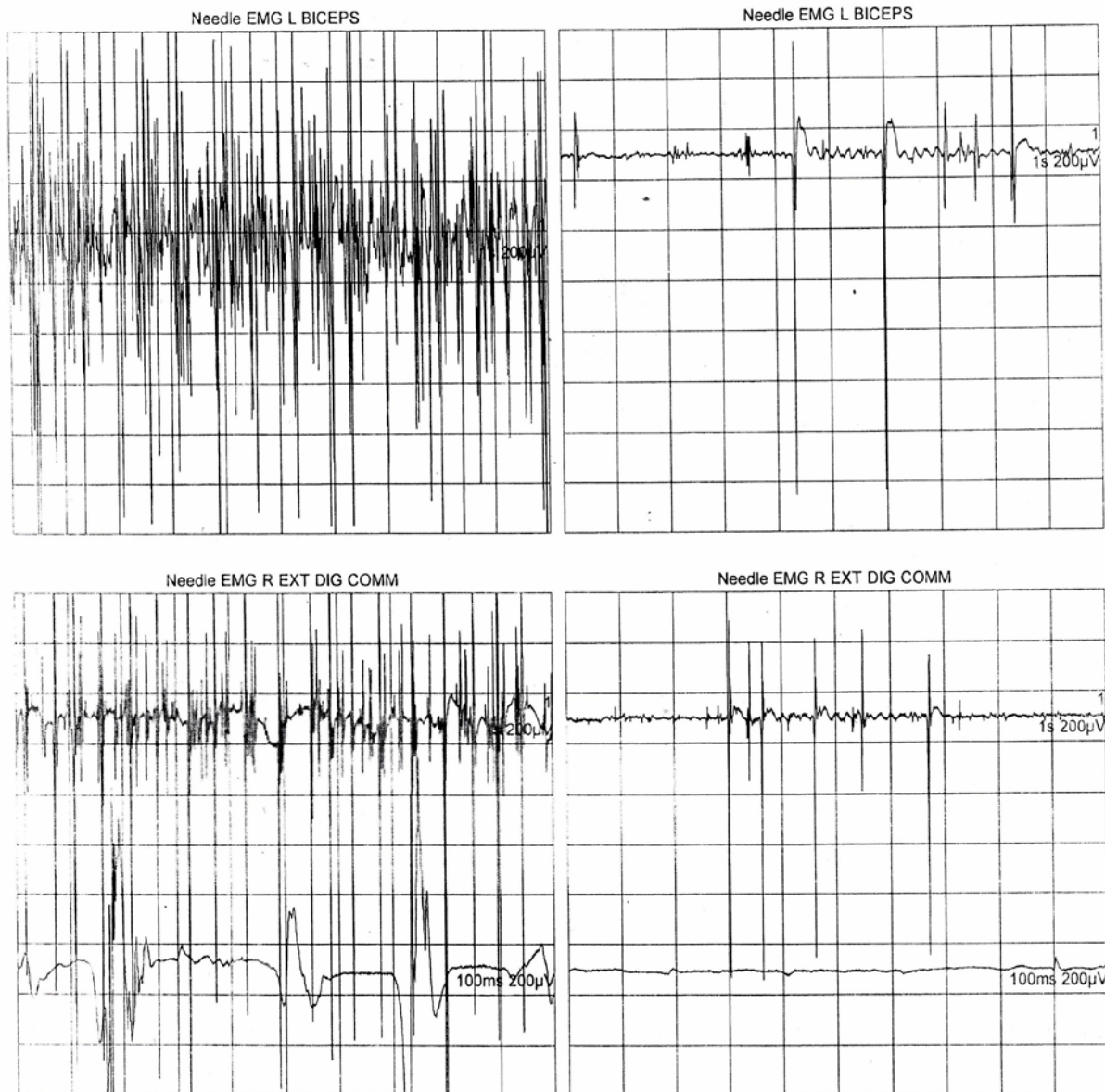
Clinical neurologic examination established the diagnosis of neurogenic spinal atrophy, in observation for amyotrophic lateral sclerosis.

The electroneuromyography (EMG) for median and ulnar nerves pointed out the diagnosis of motor chronic demyelinating neuropathy and a needle EMG was needed for confirmation of SLA.

The electroneuromyography for tibial anterior, common extensor digitis and biceps muscles recorded an aspect of generalized chronic active neurogenic injury, characterized by spontaneous presence of fibrillation, fasciculation and positive sharp waves, reduced interference pattern by decreased motor neurons recruitment and activation, stable and instable neurogenic motor unit potentials with increased duration and amplitude (Fig.1, Fig.2, Table 1). In conclusion, the aspect was characteristic for motor neuron disease and confirmed the diagnoses of SLA.



**Fig.1. Needle EMG for tibial anterior muscle: spontaneous presence of fibrillation, fasciculation and positive sharp waves, reduced interference pattern by decreased motor neurons recruitment and activation, stable and instable neurogenic motor unit potentials with increased duration and amplitude**



**Fig.2. Needle EMG for commune extensor digitis and biceps muscle identifies the same peripheral motor neuron involvement**

**Table 1. Needle EMG for tibial anterior, biceps and commune extensor digitis muscles highlights an aspect of chronic active generalized neurogenic injury characteristic for motor neuron disease (SLA)**

EMG Summary Table	Spontaneous					MUAP			Recruitment
	IA	Fib	PSW	Fasc	H.F.	Amp	Dur.	PPP	Pattern
<b>L. TIB ANTERIOR</b>	N	2+	1+	2+(slow)	None	Giant	3+	3+	Reduced
<b>R. TIB ANTERIOR</b>	N	1+	3+	None	None	Giant	3+	3+	Discrete
<b>L. BICEPS</b>	N	2+	1+	2+(slow)	None	2+	3+	3+	Reduced
<b>R. EXT DIG COMM</b>	N	1+	1+	2+(fast)	None	Giant	3+	3+	Reduced

The patient was guided towards the Neurology ambulatory service for specific treatment. During the hospitalization period she underwent rehabilitation physical and kinetic treatment, with a positive response to electrostimulation procedures for lower limbs muscles (tibial anterior, common extensor digitis). Kinesitherapy consisted in gentle, low-impact aerobic exercise including walking and stationary bicycling that can strengthen unaffected muscles, improve cardiovascular health and helped the patient fight fatigue and depression. Range of motion and stretching exercises can help prevent painful spasticity and contracture of muscles.

At the moment, the patient is under neurological supervision and underwent physical and kinetic treatment twice a year. The rehabilitation treatment improved her physical and mental condition and increased her quality of life.

## Discussion

The diagnosis of ALS is based on the presence of symptoms, signs and laboratory evidence consistent with progressive upper and lower motor neuron dysfunction, with no alternative experience. There is no widely accepted diagnostic test for ALS. Neuro-imaging and other laboratory tests are used to exclude other diseases, while electrodiagnostic tests are used to support the diagnosis. Classic presentation of ALS include asymmetric weakness of extremities (60-80%), bulbar muscles (1-9%), axial onset with head drop or truncal-extensors weakness, muscle atrophy, fasciculations and cramps (5-7%).

Although diagnostic criteria for ALS were revised in 2000, lack of a sensitive diagnostic test is a major obstacle to early diagnosis of the patients [8,10,11].

When first seen, our patient had asymmetric weakness of extremities that would be consistent with ALS. Asymmetric weakness is also consistent with an acquired neuropathic process with demyelinating features [12,13]. Fasciculations were present and are a characteristic clinical finding in ALS, but this symptom can be related to neuropathic dysfunction. Fasciculations, however, are not considered of clinical significance for ALS without associated evidence of neurogenic changes of needle EMG in the motor units recorded as fasciculations [9].

Electrodiagnostic analysis in patients with possible ALS is critical for the ALS diagnostics

itself, but also for orientating towards other potentially treatable diagnosis.

Weight loss is usually a late manifestation and has never been noted as initial complaint. The etiology of weight loss in ALS is multifactorial: impaired nutrition due to dyspnea while eating, dysphagia, weakness in extremities, difficulty with mastication and hypermetabolic state have been proposed [14,15]. Weight loss and  $BMI < 18.5 \text{ kg/m}^2$  has been associated with shortened survival and is a negative prognostic indicator [15,16]. Our patient had a  $BMI = 17.7 \text{ kg/m}^2$ .

Establishing the diagnosis of SLA was a real a challenge and a multidisciplinary evaluation was necessary. It is a very rare situation that a patient with this disease addresses a Medical Rehabilitation service for the first visit to a clinician.

## Conclusion

Although the life expectancy of a person with ALS averages about two to five years from the diagnosis, its evolution is variable and many people can live with the disease for five years and more. ALS is a difficult condition to diagnose. There is not one test or procedure to ultimately establish the diagnosis of ALS. It is through a clinical examination and a series of diagnosis tests, often ruling out other diseases that mimic ALS, that a diagnosis can be established: electrodiagnostic tests including EMG and nerve conduction velocity, blood and urine study including high resolution serum protein electrophoresis, thyroid and parathyroid hormone levels and 24-hours urine collection for heavy metals, X-rays, including magnetic resonance imaging (MRI), muscle and/or nerve biopsy, a neurological examination. In our case, the clinical neurological examination and electromyographic tests led to the diagnosis of ALS.

## References

1. Gordon PH. Amyotrophic lateral sclerosis: an update for 2013: clinical features, pathophysiology, management and therapeutic trials. *Aging Dis*, 2013, 4(5):295-310.
2. Kiernan MC, Vucic S, Cheah BC, Turner MR, Eisen A, Hardiman O, Burrell JR, Zoing MC. Amyotrophic lateral sclerosis. *Lancet*, 2011, 377(9769):942-955.
3. Miller RG, Mitchell JD, Moore DH. Riluzole for amyotrophic lateral sclerosis (ALS)/motor neuron disease (MND). *Cochrane Database Syst Rev*, 2012, 3:CD001447.
4. Bowser B, Turner MB, Shefner J. Biomarkers in amyotrophic lateral sclerosis: opportunities and limitations. *Nat Rev Neurol*, 2011, 7(11):631-638.

5. Meininger V. ALS, what new 144 years after Charcot?. *Arch Ital Biol*, 2011, 149(1):29-37.
6. Li D, Shen D, Tai H, Cui L. Neurofilaments in CSF as diagnostic biomarkers in motor neuron disease: a metaanalysis. *Front Aging Neurosci*, 2016, 8:290.
7. Brooks BR. El Escorial World Federation of Neurology criteria for the diagnosis of amyotrophic lateral sclerosis. Subcommittee of Motor Neuron Diseases/Amyotrophic lateral sclerosis of the World Federation of Neurology Research Group on Neuromuscular Diseases and the El Escorial „Clinical limitations of amyotrophic lateral sclerosis” workshop contributors. *J Neurol Sci*, 1994, 124(Suppl):96-107.
8. Brooks BR, Miller RG, Swash M, Munsat TL. World Federation of Neurology Research Group on Motor Neuron Diseases. El Escorial revised criteria for the diagnosis of amyotrophic lateral sclerosis. *Amyotroph Later Scler Other Motor Neuron Disord*, 2000, 1(5):293-299.
9. de Carvalho M, Dengler R, Eisen A, England JD, Kaji R, Kimura J, Mills K, Mitsumoto H, Nodera H, Shefner J, Swash M. Electrodiagnostic criteria for diagnosis of ALS. *Clin Neurophysiol*, 2008, 119(3):497-503.
10. Li TM, Alberman E, Swash M. Clinical features and associations of 560 cases of motor neuron disease. *J Neurol Neuro-surg Psychiatry*, 1990, 53(12):1043-1045.
11. Talbot K. Motor neuron disease. *Postgrad Med J*, 2002, 78(923):513-519.
12. De Sousa EA, Chin RC, Sander HW, Latov N, Brannigan TH. Demyellinating findings on typical and atypical chronic inflammatory polyneuropathy: sensitivity and and specificity. *J Clin Neuromuscul Dis*, 2009, 10(4):163-164.
13. Saperstein DS, Katz JS, Amato A, Baron RJ. Clinical spectrum of chronic acquired demyelinating polyneuropathies. *Muscle Nerve*, 2001, 24(3):311-324.
14. Desport JC, Preux PM, Magy L, Boirie Y, Vallat JM, Beaufriere B, Couratier P. Factors correlated with hypermetabolism in patients with amyotrophic lateral sclerosis. *Am J Clin Nutr*, 2001, 74(3):328-334.
15. Desport JC, Preux PM, Truong TC, Vallat JM, Sautereau D, Couratier P. Nutritional status is a prognostic factor for survival in ALS patients. *Neurology*, 1999, 53(5):1059-1063.
16. Kasarskis EJ, Berryman S, Vanderleest JG, Schneider AR, Mc Clain CJ. Nutritional status of patients with amyotrophic lateral sclerosis: relation to the proximity of death. *Am J Clin Nutr*, 1996, 63(1):130-137.

---

***Corresponding Author: Simona Patru, Department of Physical Medicine and Rehabilitation,  
University of Medicine and Pharmacy of Craiova, Romania, 2-4 Petru Rares St, Craiova, Romania,  
e-mail: s\_patru@yahoo.com***