

The Sutton's Foramen of the Oblique Line of Mandible

MUGUREL CONSTANTIN RUSU¹, MIHAI DRAGOMIR STOENESCU²

¹Division of Anatomy, Faculty of Dental Medicine,
„Carol Davila” University of Medicine and Pharmacy, Bucharest, Romania

²Division of Anatomy, Faculty of Dental Medicine,
„Carol Davila” University of Medicine and Pharmacy, Bucharest, Romania;
„Dr. Carol Davila” Central Military Emergency University Hospital, Bucharest, Romania

ABSTRACT: Although the foramina of the adult mandible are well known and extensively studied, still additional foramina and canals could persist from the fetal stage and be detected occasionally in adult. At a routine anatomical evaluation of the Cone Beam Computed Tomography (CBCT) scan of a female patient of 47 years old, a rare anatomical variant of the mandible was found, and is presented here. It was termed foramen lineae obliquae and it was found in the right hemimandible at the level of the second molar, on the oblique line. From that foramen a canal continued within the mandible to join the mandibular canal. On orthogonal slices was accurately detected that the content of that foramen and canal was connected to an intramasseteric network, which was strongly suggestive for that content being vascular. Although a contribution from the buccal nerve could not be withdrawn, the most reasonable content to speculate is the aberrant anastomotic artery of the facial and inferior alveolar arteries. Vascular foramina of the mandible are relevant during various surgical procedures. Surgeons should be aware that if an artery is commonly regarded as a supplier of a muscle inserted on the mandible, it should not be rejected a priori the possibility for that artery being also an extrinsic supplier of the mandible, through an unexpected foramen in the vicinity of that muscle.

KEYWORDS: Mandible, Cone Beam Computed Tomography, foramen, facial artery, masseter muscle.

Introduction

Although the foramina of the adult mandible are well known and extensively studied, still additional foramina and canals could persist from the fetal stage, being detected occasionally in adult.

Sutton described in 1974 a relatively large foramen (Figure 1) lying buccally near the lower part of the anterior border of a dry mandibular ramus, which was comparable in size with the mental foramen [1].

Moreover, he found, but he did not present that evidence, in one dissection, a foramen which was located distal to the lower third molar, which was traversed by a neurovascular bundle, which included a branch from the buccal nerve [1].

The Sutton's foraminae of the oblique line were largely overlooked. Such a rare anatomic variation is therefore reported here, being the first such evidence in Cone Beam CT (CBCT), to our knowledge.

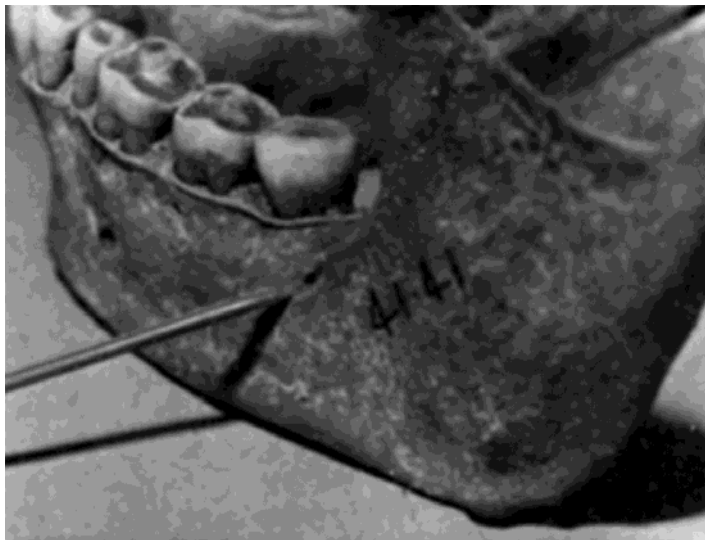

Figure 1. Sutton's foramen is located distally to the third mandibular molar, on the oblique line. The original description was „A large accessory foramen buccal to the anterior border of the left ramus of a mandible”. Reprinted with permission from John Wiley and Sons (License Number: 4816331122996) from [1].

Material and Method

At a routine anatomic evaluation in CBCT of the scan of a female patient of 47 y.o., a rare anatomic variant foramen of the mandible was found.

The patient has been scanned with an iCat CBCT machine (Imaging Sciences International, resolution 0.250, FOW 130, image matrix size 640x640).

Collected data were evaluated both with the iCatVision software and the Planmeca Romexis Viewer 3.5.0.R software, as previously detailed [2,3].

The second software was used for three-dimensional volume renderisations.

Relevant anatomical features were exported as image files.

The patient has given written informed consent for all medical data (including CBCT scans) to be used for research purposes, and the presented results were anonymized.

The study was approved (372/18.03.2020) by the responsible authorities (2nd affiliation of the second author).

Results

On the external surface of the right hemimandible, we identified a foramen of a caliber of 1.41mm, on the posterior end of the oblique line (Figure 2). The finding was unilateral.

It was termed *foramen lineae obliquae*, or the foramen of the oblique line.

That foramen was located at 7.85mm external to the distal side of the distal root of the second mandibular molar, and was opened postero-superiorly towards a groove on the oblique line.

A canal was connecting the *foramen lineae obliquae* with the mandibular canal, and was digitally reconstructed (Figure 2).

On orthogonal cuts, the images suggested (Figure 3 and 4) the connection of the content of that foramen and canal with a network/plexus within the anterior border of the masseter muscle.

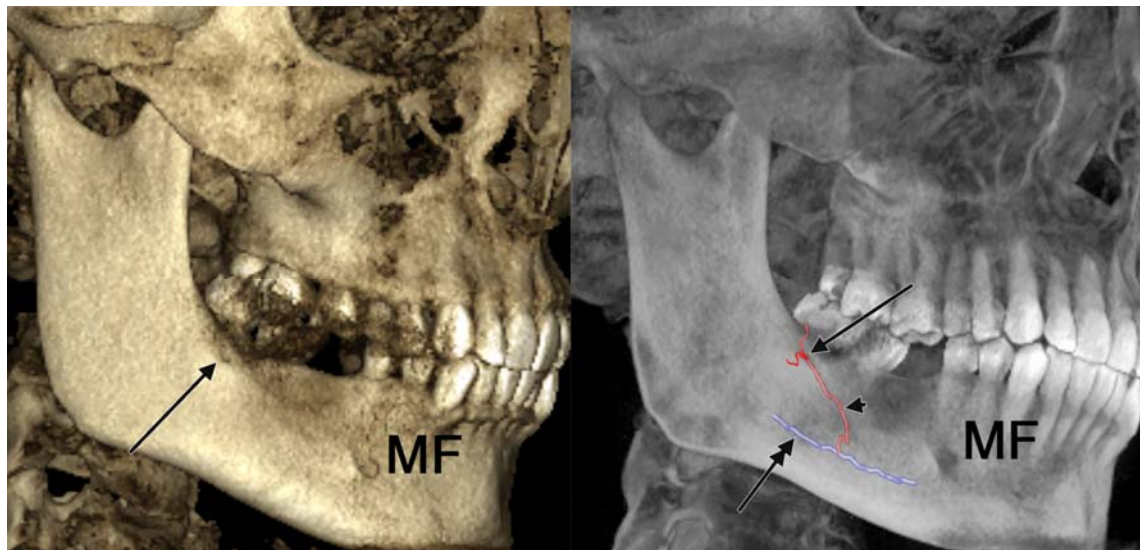


Figure 2. Three-dimensional renderisations of the right hemimandible, lateral views (left: Xray Shaded Filter, right: B&W Xray Filter, with reconstructions of canals). The arrows indicate the foramen of the oblique line which is connected through a canal (arrowhead) with the mandibular canal (double-headed arrow). MF: mental foramen.

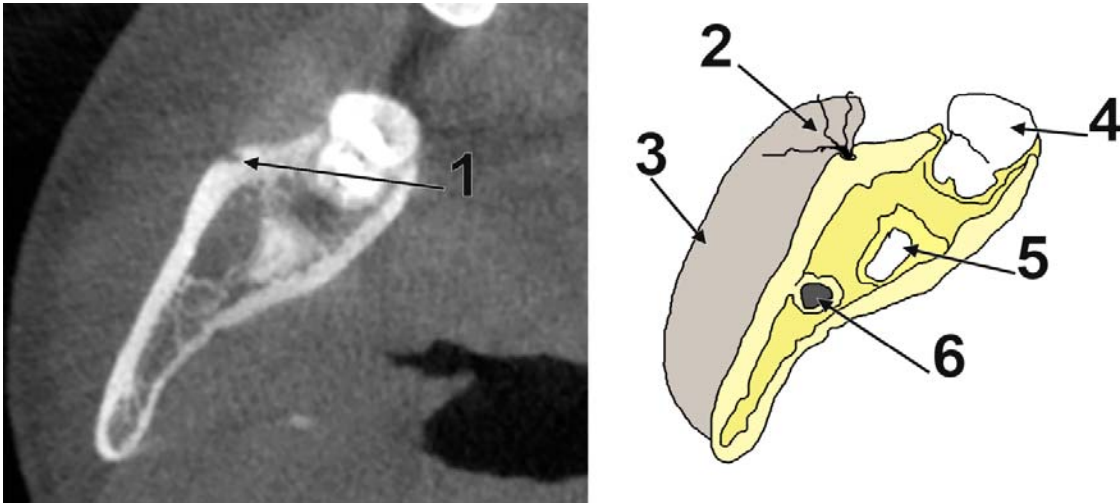


Figure 3. Axial slice through a buccal foramen on the oblique line, located distally to the left second mandibular molar, in a case with partial impaction of the respective third molar.
1. foramen of the oblique line; 2. a plexus within the anterior border of the masseter muscle is connected to the foramen of the oblique line; 3. masseter m.; 4. second mandibular molar; 5. root of the impacted third mandibular molar; 6. mandibular canal.

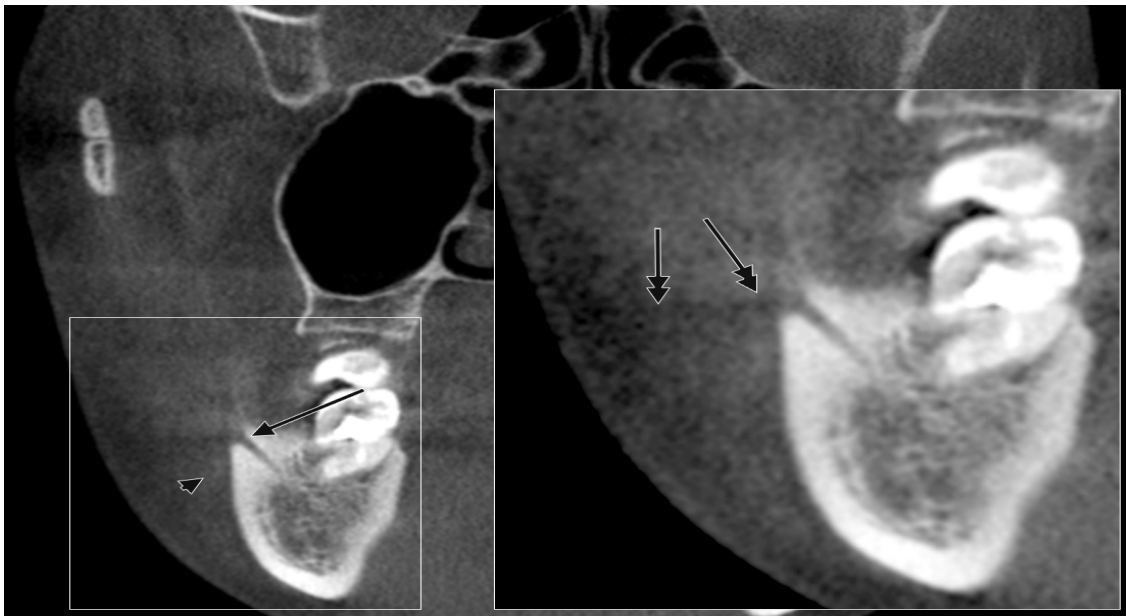

Figure 4. Orthogonal coronal cut through the foramen of the oblique line (arrow). The masseter muscle is indicated (arrowhead). In the inset (digitally magnified) a trajectory (double-headed arrows) through the anterior border of the masseter muscle is seemingly sending ascending and descending branches which dichotomize and build a network within the muscle.

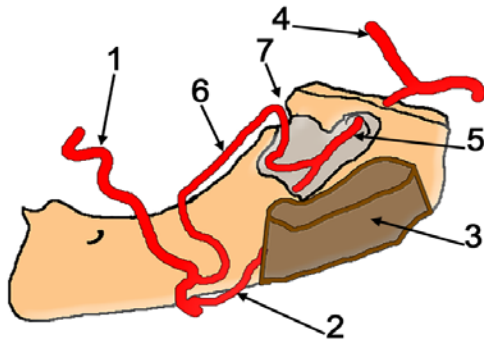


Figure 5. Modified after Bhattacharya et al. 2020 [7]. 1. facial a.; 2. premasseteric a.; 3. masseter m.; 4. maxillary a.; 5. inferior alveolar a.; 6. aberrant anastomotic artery between facial and inferior alveolar aa.; 7. foramen at the distal end of the oblique line.

Discussion

Accessory foramina that relate to the mandibular canal are clinically important in endodontic treatments and surgical procedures [4].

Moreover, foramina on the lateral surface of the mandible, such as in the present case, could provide direct channels for invasion of tumour cells from the lateral surface to the medulla [5].

Noteworthy, if one identifies foramina and canals in CBCT, the neurovascular content of these could only be presumed.

Except the mental foramina which serve for the passage of the mental nerve or its branches, foramina on the lateral surface of the mandible could be nutrient foramina supplied by various arteries, such as the buccal and facial arteries [4].

In these regards, the Sutton's foramen of the oblique line we found in CBCT could be only speculated as a vascular foramen/canal. Such foramen could be supplied either with a branch of the inferior alveolar artery for the network within the masseter muscle, or by a branch descending from the premasseteric branch of the facial artery, or directly from the facial artery.

On other hand, the foramen of the oblique line could equally allow passage for a nerve branched from the buccal nerve to enter the mandible and supply accessory innervation of lower teeth. Regarding the buccal nerve supply, it usually covers a small territory, at the second premolar and first molar teeth [6], being thus expected a mandibular distribution through minute buccal foramina and not through a large foramen at the distal end of the oblique line.

We serendipitously found a recent report of a "unique anastomosis between facial and inferior

alveolar arteries, vessels that have not been previously shown to communicate" (Figure 5) [7].

Interestingly, the authors demonstrate beyond any doubt by dissection an "aberrant artery" of 1.3mm. calibre, which left the facial artery on the mandible's body, distally to the origin of the premasseteric artery, coursed beneath the anterior border of the masseter muscle and curved down to enter the mandible to anastomose with the inferior alveolar artery [7].

Although the authors indicated it entered the mandible's ramus, the evidence they presented demonstrate the situs of entrance at the posterior border of the buccinator muscle [7], thus at the distal end of the oblique line, such as is also positioned the foramen of the oblique line we report here. Therefore, we could not exclude that such foramina of the oblique line use for facial-to-inferior alveolar arteries anastomoses. Moreover, as this aberrant artery courses beneath the masseter muscle, contributions to the masseteric plexus appear natural. A masseteric supply from the facial artery was demonstrated in fetuses [8] as well as in adults [9].

We could not find reports to indicate a masseteric supply from the inferior alveolar artery.

Therefore, although a neural supply of the foramen of the oblique line could not be excluded in CBCT, a possible vascular content is bona fide a possible one. Therefore, beyond the academic interest in anatomic variations, the foramen of the oblique line of the mandible is of relevance for different surgical procedures (craniofacial, maxillofacial, orthodontic, traumatology, or plastic surgery), such as are transpositions for facial palsies, benign masseteric hypertrophy, or neurectomy-induced atrophy of the masseter muscle corrections, flap procedures, or facial reconstructions after oncologic surgery [10-12].

Iatrogenic conditions and bleeding could be avoided if care is taken during the separation of the anterior border of the masseter muscle from the mandible, peculiarly during masseter muscle flap formation, mandibular angle resection, or mandibular ramus osteotomy [13].

Therefore, if an artery is commonly known as a supplier of a muscle inserted on the mandible, it should not be rejected *a priori* the possibility for that artery being also an extrinsic supplier of the mandible, through an unexpected foramen in the vicinity of that muscle.

Acknowledgement

None.

Conflict of interests

None to declare.

References

1. Sutton RN. The practical significance of mandibular accessory foramina. Australian dental journal, 1974, 19(3):167-173.
2. Rusu MC, Sava CJ, Ilie AC, Sandulescu M, Dinca D. Agger Nasi Cells Versus Lacrimal Cells and Uncinate Bullae in Cone-Beam Computed Tomography. Ear Nose Throat J, 2019, 98(6):334-339.
3. Rusu MC, Sandulescu M, Sava CJ, Dinca D. Bifid and secondary superior nasal turbinates. Folia Morphol (Warsz), 2019, 78(1):199-203.
4. Sisman Y, Sahman H, Sekerci A, Tokmak TT, Aksu Y, Mavili E. Detection and characterization of the mandibular accessory buccal foramen using CT. Dento maxillo facial radiology, 2012, 41(7):558-563.
5. Fanibunda K, Matthews JN. Relationship between accessory foramina and tumour spread in the lateral mandibular surface. Journal of anatomy, 1999, 195 (Pt 2):185-190.
6. Sicher H. The anatomy of mandibular anesthesia. Journal of the American Dental Association, 1946, 33(23):1541-1557.
7. Bhattacharya A, Sharma R, Armstrong C, Solis L. Case report of unique anastomosis between facial and inferior alveolar arteries. Surg Radiol Anat, 2020, 42(5):603-606.
8. Hamparian AM. Blood supply of the human fetal mandible. The American journal of anatomy, 1973, 136(1):67-75.
9. Von Arx T, Lozanoff S. Masticatory Muscles. In: Clinical Oral Anatomy: A Comprehensive Review for Dental Practitioners and Researchers, Springer, 2016, Switzerland, 537-556
10. Somanath D. Variation in the branching pattern of facial artery: premassesteric artery. Int J Anat Res, 2015, 3(1):828-830.
11. Nayak SB. Triple Premassesteric Branches of Facial Artery. The Journal of craniofacial surgery, 2019, 30(2):e168-e169.
12. Magden O, Gocmen-Mas N, Senan S, Edizer M, Karacayli U, Karabekir HS. The premassesteric branch of facial artery: its importance for craniofacial surgery. Turkish neurosurgery, 2009, 19(1):45-50.
13. Won SY, Choi DY, Kwak HH, Kim ST, Kim HJ, Hu KS. Topography of the arteries supplying the masseter muscle: Using dissection and Sihler's method. Clinical anatomy, 2012, 25(3):308-313.

Corresponding Author: Mugurel Constantin Rusu, Division of Anatomy, Faculty of Dental Medicine, „Carol Davila” University of Medicine and Pharmacy, Bucharest, Romania, e-mail: mugurel.rusu@umfcd.ro