

Case Report

Ewing Sarcoma of Fibula: A Pediatric Case of Disease Regression and Bone Regeneration. Case Report and Literature Review

CODRUT VLAD STRIMBU¹, ALIN BOGDAN DEACANU¹,
ANDREI-CRISTIAN ESANU¹, ANDREI-EDUARD LUCA¹,
STEFAN NICOLAE CRACANA²

¹"Carol Davila" University of Medicine and Pharmacy, Bucharest, Romania

²Department of Pathology, Colentina Clinical Hospital, Bucharest, Romania

ABSTRACT: Ewing's sarcoma is a rare type of bone malignancy that occurs mostly in the bones of the pelvis and the limbs. We report a case of Ewing's sarcoma developed in the peroneal bone of a 10-year-old boy, with a severe affection of the bone and pulmonary metastasis. Chemotherapy was administered to the patient. Approximately two years after first presentation, radiological exams indicated a nearly complete regenerated fibula and PET-CT scan indicated an inactive right lung mass. This case showed the incredible potency of recovery in pediatric patients and highlights the need for a personalized approach in pediatric orthopedic oncology.

KEYWORDS: Ewing sarcoma, fibula, bone tumor, childhood cancer, pulmonary metastasis.

Introduction

Ewing's sarcoma (ES) is an aggressive bone malignancy that mainly affects children and adolescents, usually occurring between the ages of 10 and 20 years [1,2].

When compared with other cancers, bone tumors like ES are uncommon, the annual incidence being approximately 0.6/million of the total population [3].

Nevertheless, ES is responsible for 3.5% of all cancers in American children with ages 10 to 14, and for 2.3% in those between 15 and 20.

ES can appear in any bone, yet it generally affects the long bones. ES can interest the soft tissue surrounding the bones, such as cartilage, muscles or the nerves and occasionally the tumor begins in these structures (being called extraosseous ES). Due to recent discoveries, the disease has been defined as part of a spectrum, referred to as Ewing sarcoma Family of Tumor (EFT). It includes the ES of bone, ES of soft tissue, primitive neuroectodermal tumor (PNET) which may develop in both bone and soft tissue, Askin's tumor, a PNET that occurs in the bones of the thorax and atypical ES [4].

Historically, the first reference of the disease was made in 1918 by Stout et al. [5] which reported an round cell tumor, originated in the ulnar nerve, thus later proposing the naming of neuroepithelioma [6].

Later, in 1921, Ewing described a round cell sarcoma in the radius in a 14-year-old patient,

referring to it as a "diffuse endothelioma of the bone" [6,7].

The existence of an ES of extraskeletal origin was first reported by Angervall and Enzinger [6].

In 1976, Nesbitt and Vidone first described a PNET.

In the 1980s, chromosome investigations of the ES cell lines detected a t(11;22)(q24;q12) translocation [6]. The EWS-FLI1 mutated gene, as a result of a translocation between gene FLI1 on chromosome 11q24 and EWS on chromosome 22q12 was described in 1992 [6].

In recent years, molecular techniques proved useful for detecting fusion genes, the most common ones being the EWS-FLI1 (in 85% of cases) and EWS-ERG (10% of cases) [6].

Although the involvement of cell DNA mutations was demonstrated, the definite cause of the ES is still unclear, as it does not appear to run in families, or to be associated with specific congenital syndromes [2].

So far, research suggests that it is not related to radiation exposure, chemicals, or the substances in the environment. Moreover, the tumor does not seem to develop as a result of social, dietary, or behavioral habits.

The aim of this article is to present a pediatric case of ES that had an impressive disease regression and bone regeneration following the oncologic treatment. A literature review of the clinical aspects, genetics, histology and immunohistochemistry and treatment of ES is also provided.

Case Presentation

We report on a case of a 10-year-old male patient, that was referred to the healthcare unit for pain and progressively swelling in the left fibula area.

Physical examination showed a fixed, hard in consistency, expansive mass in the affected zone with no other pathological signs.

A lower extremity X-ray (Figure 3a) and CT scan revealed an expansive osteolytic process, with important bone destruction in the left fibula region, $\frac{3}{4}$ proximal of the metaphysis-diaphysis area.

No demarcation line could be established, but a transition zone, measuring 52/66mm in axial plan and 192mm in medial plan was determined.

A CT scan of the chest showed both lungs at their physiological expansion capabilities together with multiple, low-iodophilic nodular and macronodular deossifications at the pulmonary parenchyma level.

The biggest one measured 41/34mm in axial plan, being located in the left lower lobe.

No signs of calcification, pleural and pericardial effusion or mediastinal lymphadenopathy were present.

A hypertrophic left liver lobe was identified.

A left inguinal lymphadenopathy of 13/7mm was discovered.

No free intraperitoneal fluid was identified.

A cerebral CT scan revealed a normal and symmetrical ventricular system, without pathological zones of contrast or anomalies concerning the bone structure.

The MRI exam showed an osteolytic tumor with a starting point in the proximal left peroneal diaphysis was observed with the dimensions 130x70x60mm.

The tumor appeared to be delimited by adjacent muscle structures.

It also displaces the anterior tibial bundle, but includes the posterior tibial and peroneal vascular bundles.

Medullary extension beyond the proximal and distal limit of the tumor was also revealed.

Practitioners considered this description compatible with the diagnosis of fibula osteosarcoma.

An excisional bone biopsy was performed the following day.

The histopathological exam of the tumor showed small, round cells, with quantitatively reduced pale cytoplasm, imprecise cell boundaries, with round, hyperchrome, monomorphic nuclei, and also homogeneous

chromatin, with rare punctate nucleoli and rare mitosis; the cells are arranged in solid sheets, with reduced connective tissue (Figure 1) surrounded by striated muscle tissue with distorted architecture (Figure 1), indicative of classic ES.

Immunohistochemical staining was done at Victor Babeş Institute using two-step indirect methods with 1:100 dilutions and Leica DM750 microscope with Leica ICC50W camera.

The used markers were Common Leucocyte Antigen (CLA) clone RP2/12 produced by Leica, desmin clone D33 produced by ImmunoLogic, and CD99 clone PCB1 produced by Leica.

It was found positive for CD99 antigen (Figure 2a), and negative for desmin protein in the tumorous cells (Figure 2b), allowing for differential diagnostic with embryony rhabdomyosarcoma.

Immunohistochemistry was negative for CLA antigen in tumor cells, but positive in lymphocytes associated with tumor proliferation (Figure 2c), making the differential diagnosis with small cell lymphoma.

After the diagnostic, multi agent chemotherapy was initiated considering the presence of pulmonary metastasis.

It consisted of alternating cycles at around 3 weeks' interval.

The first cycles consisted of cisplatin, ifosfamide and etoposide, second cycle of cyclophosphamide, doxorubicin, dactinomycin and cisplatin and the third cycle of cyclophosphamide, methotrexate and vincristine.

The last cycle was 7 months from the initiation of the treatment and all doses were in the low range.

Ifosfamide was always administered together with mesna for decreasing the risk of bladder bleeding.

Supportive therapy with filgrastim (for reducing neutropenia), granisetron (as antiemetic), allopurinol (reduce uric acid), loop diuretic (furosemide), hydrocortisone hemisuccinate, ibuprofen, vitamins B1, B6, C, Ca, Mg, arginine, dextrose was maintained during the entire treatment period.

Approximately two years after first presentation, a PET-CT scan indicated an inactive right lung mass and the radiological exams indicated a nearly complete regeneration of the fibula (Figure 3b).

A written informed consent of the caretakers approved the publication of this material.

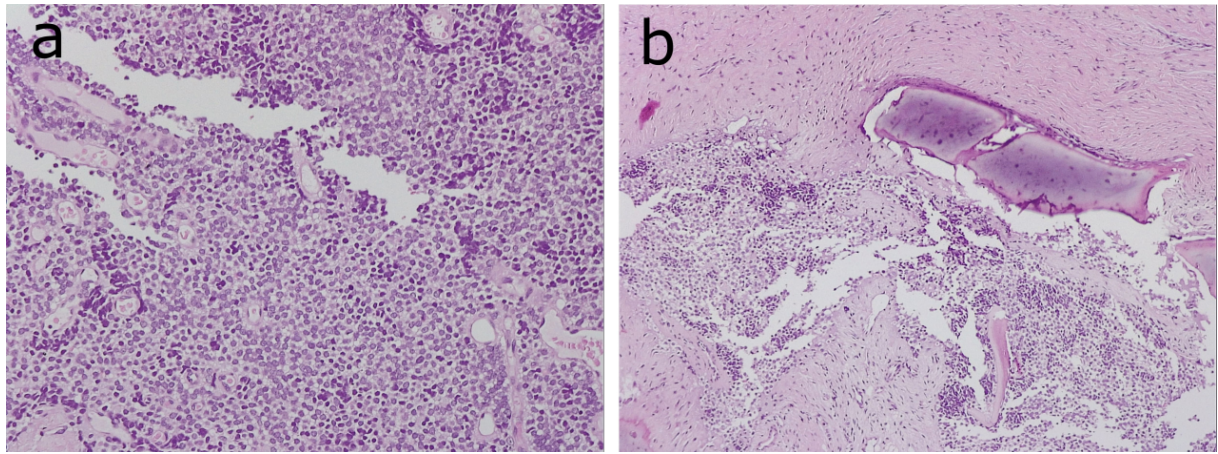


Figure 1. Tumor histological exam showing small round cells with reduced cytoplasm and hyperchrome nuclei (a) (H&E staining, X20) and bone fragments with tumor infiltration with an classic Ewing sarcoma aspect (b) (H&E staining, X10).

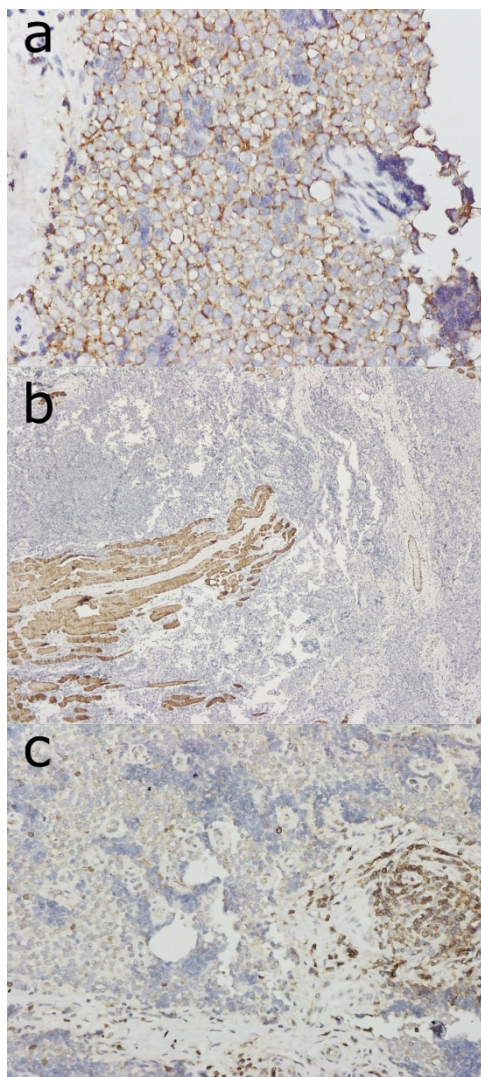


Figure 2. Immunohistochemical staining with CD99 antigen positive for cell membrane (X40 figure 2a), with desmin, negative for tumor cells and positive for striated muscle fibers (X10 figure 2b) and with cutaneous lymphocyte-associated antigen (CLA), negative for tumor cells negative and positive for the lymphocytes associated with tumor proliferation (X20 figure 2c).

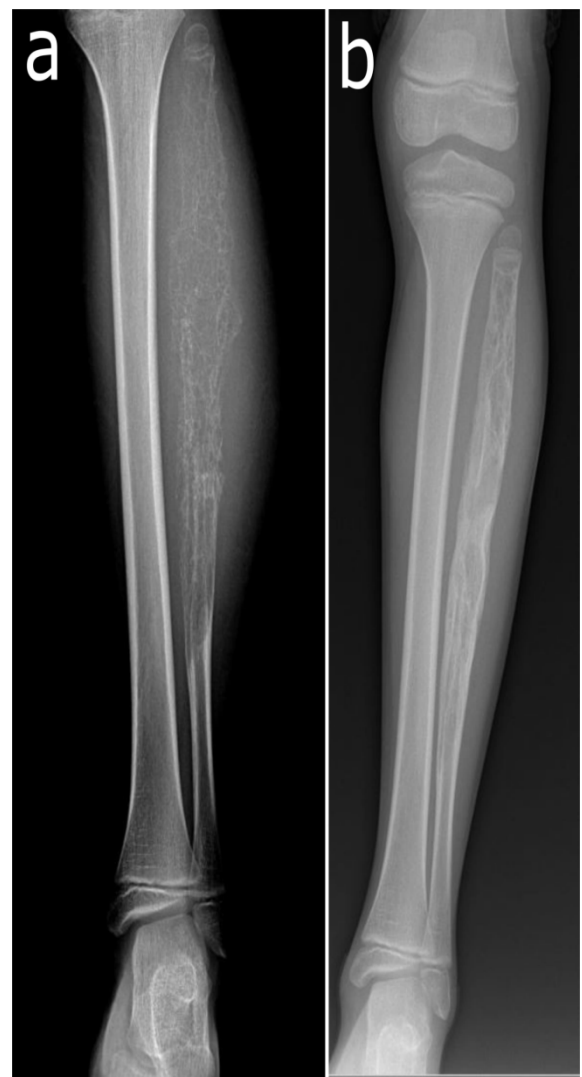

Figure 3. X-ray of the left fibula at presentation (a) and the end of the chemotherapeutic treatment (b).

Discussions

The primary sites of ES are the long bones of the limbs (mostly femur, but also tibia, fibula and humerus) and the bones of the pelvis. Less often affected are the spine, hands and feet [8].

Fibular sarcoma is present in around 6.7% of the cases [8].

Patients typically come with localized pain or swelling, often worse at nights. About 20% of patients have fever, fatigue, weight loss or anemia at presentation [4].

Approximatively 80% of patients have a localized disease, but a subclinical metastasis is probable as the delay between the onset of the symptoms and diagnostics is around nine months [9].

Patients with primary pelvic tumors are more likely to have metastatic disease [8].

Also, patients with a higher lactic dehydrogenase (LDH), fever, age over 12 years and interval between onset of symptoms and diagnosis less than three months gave a much higher risk of metastasis [10].

The predominant site of metastasis is the lung and bone (mostly spine) or bone marrow in relatively equal proportions. Lung metastasis represents the leading cause of death [4].

Our case presented the typical signs and symptoms, with the only mention that the presentation was delayed until the symptoms intensified.

In terms of histology, histogenetic origin of the tumor is not clear, with some studies suggesting the neural crest as the most likely progenitor due to its similarities with classic neuroblastoma [11].

The classical ES has the morphological appearance of an undifferentiated neoplasm. It is formed by uniform small round tumor cells in sheets with round nuclei. The cytoplasm is small and does not exhibit matrix formation (Figure 1). Morphological characteristics that are suggestive for neural differentiation such as rosette formation can be present [6].

The cells are having periodic acid-Schiff (PAS) positive granules in the cytoplasm as the contain high amount of glycogen. Immunohistochemically, the cells are sometimes positive PGP9.5 and S-100 protein as neural markers and also for vimentin [6].

In around 90% of cases positivity for CD99 is present in the membrane. Nevertheless, CD99 positivity is not specific to ES, being also present in lymphoma, lymphoblastic leukemia and other cancers [12].

Another new potential marker for ES is NKX2.2, the protein produced by NKX2-2 gene [13].

Cytogenetic studies and molecular genetic studies that examine chromosomal translocations and their fusion transcripts are useful in establishing a firm diagnostic [2].

Due to resource availability, our patient had only histological and immunohistochemistry work-up performed, but the results indicated clearly a case of classic ES.

After diagnostic, several factors have been found useful in determining prognosis and therapy intensity: presence of metastases, primary tumor location, tumor size and volume, tumors located in the axial skeleton, histological response to therapy, patient age and presence of certain chromosomal translocations [4,14].

Presence of metastases represents an important prognosis factor, with a five-year survival rate of 70% for no metastasis compared to 33% for those who have metastases. Some studies have found that isolated lung metastases have a better prognostic than bone or bone and lung metastases [8], but newer systematic reviews question this finding [14].

In terms of size and volume, a volume larger than 200ml or a diameter larger than 8 cm show poorer event free survival. In terms of age, there is evidence that younger age improves survival. Mutations of the short arm of chromosome 1p, deletions of CDKN2A and p16/p14ARF, and p53 mutations have been associated with poorer prognosis and worse response to chemotherapy [4].

Other factors such as disease free tumor margins after surgical resection, race and serum LDH require further investigations. Our patient presented with multiple negative prognostic factors such as pulmonary metastasis and large tumor size, with only younger age being a positive one.

Treatment guidelines have been developed from both European [15] and American [16] medical bodies. It includes treatment for the localized disease and for the metastatic ones.

However, considering that the majority of cases have subclinical metastasis, multiagent chemotherapy is used and has a strong impact on survival [17,18].

The present trials include 3 to 6 cycles of initial chemotherapy, being followed by local therapy and another 6 to 10 cycles applied at 2 to 3 weeks' interval. The most active agents include cyclophosphamide, doxorubicin

(Adriamycin), dactinomycin, ifosfamide, vincristine and etoposide [15,19,20].

For patients with localized disease, standard dose VAC/IE (vincristine, doxorubicin, and cyclophosphamide alternating with ifosfamide and etoposide) is preferred. For patients with metastatic disease studies have shown that the addition of ifosfamide and etoposide (IE) does not bring specific benefits. Dose intensified treatments (VDC/IE augmented with alkylator doses) are considered not to improve the outcome by some studies [21], but new approaches in using this technique are thought to do it [22].

Interval-compressed VDC/IE were associated with a positive outcome in pediatric patients [23].

The addition of monoclonal antibodies to standard chemotherapy are currently investigated in the Children's Oncology Group trial [24].

Novel agents that use targeted therapy on inhibiting insulin-like growth factor 1 receptors can represent new strategies for future treatment [25].

Improved outcomes can be achieved when chemotherapy is combined with radiation and site resection. It is still debated if radiotherapy alone is worse than surgery with or without radiotherapy, but other systematic literature found that either surgery alone or radiotherapy alone are equitable treatment options [14].

Although the prognosis for patients with ES has improved in the recent years, survival rates, especially for the ones with metastases, are low.

Even though the long term prognosis for this patient is unclear, unexpected positive developments underline the unpredictable nature of pediatric oncology.

This case showed the incredible potency of recovery in pediatric patients and highlights the need for a personalized approach in treatment of ES.

Acknowledgments

We would like to thank Dr. Herdea Alexandru, Dr. Ulici Alexandru, Dr. Oana Neagu and Dr. Stanciu Albert from Grigore Alexandrescu" Clinical Emergency Hospital for Children, Bucharest, Romania for their vital support and collaboration.

Conflict of interests

The authors declare that they have no conflict of interests.

References

1. Chatzistefanou I, Kabesi S, Paraskevopoulos K, Kolioukas D, Antoniadis K. Ewing's Sarcoma of Mandible: An Impressive Case of Spontaneous Mandible Regeneration. *Int J Clin Pediatr Dent*, 2016, 9(3):273-277.
2. DeLaney TF, Hornicek FJ, Bahrami A. Epidemiology, pathology, and molecular genetics of the Ewing sarcoma family of tumors. In: Post T (Eds): *UpToDate*, UpToDate, 2020, Waltham, MA, USA, 0.
3. Burchill SA. Ewing's sarcoma: diagnostic, prognostic, and therapeutic implications of molecular abnormalities. *J Clin Pathol*, 2003, 56(2):96-102.
4. DeLaney TF, Hornicek FJ. Clinical presentation, staging, and prognostic factors of the Ewing sarcoma family of tumors. In: Post T (Eds): *UpToDate*, UpToDate, 2020, Waltham, MA, USA, 0.
5. Stout AP. A tumor of the ulnar nerve. *Proc NY Pathol Soc*, 1918, 12:2-12.
6. Ozaki T. Diagnosis and treatment of Ewing sarcoma of the bone: a review article. *Journal of Orthopaedic Science*, 2015, 20(2):250-263.
7. Ewing J. Diffuse endothelioma of bone ewing. *Proc NY Pathol Soc*, 1921, 21:17-24.
8. Cotterill SJ, Ahrens S, Paulussen M, Jürgens HF, Voûte PA, Gadner H, Craft AW. Prognostic factors in Ewing's tumor of bone: analysis of 975 patients from the European Intergroup Cooperative Ewing's Sarcoma Study Group. *J Clin Oncol*, 2000, 18(17):3108-3114.
9. Sneppen O, Hansen LM. Presenting symptoms and treatment delay in osteosarcoma and Ewing's sarcoma. *Acta Radiol Oncol*, 1984, 23(2-3):159-162.
10. Ferrari S, Bertoni F, Mercuri M, Sottili S, Versari M, Bacci G. Ewing's sarcoma of bone: relation between clinical characteristics and staging. *Oncol. Rep*, 2001, 8(3):553-556.
11. O'Regan S, Diebler MF, Meunier FM, Vyas S. A Ewing's sarcoma cell line showing some, but not all, of the traits of a cholinergic neuron. *J Neurochem*, 1995, 64(1):69-76.
12. Olsen SH, Thomas DG, Lucas DR. Cluster analysis of immunohistochemical profiles in synovial sarcoma, malignant peripheral nerve sheath tumor, and Ewing sarcoma. *Mod. Pathol*, 2006, 19(5):659-668.
13. Yoshida A, Sekine S, Tsuta K, Fukayama M, Furuta K, Tsuda H. NKX2.2 is a useful immunohistochemical marker for Ewing sarcoma. *Am J Surg. Pathol*, 2012, 36(7):993-999.
14. Bosma SE, Ayu O, Fiocco M, Gelderblom H, Dijkstra PDS. Prognostic factors for survival in Ewing sarcoma: A systematic review. *Surgical Oncology*, 2018, 27(4):603-610.
15. Casali PG, Bielack S, Abecassis N, Aro HT, Bauer S. Bone sarcomas: ESMO-PaedCan-EURACAN Clinical Practice Guidelines for diagnosis, treatment and follow-up. *Annals of Oncology*, 2018, 29:iv79-iv95.
16. NCCN Guidelines, 2019, Bone Cancer (version 1.2020) [online]. Available at https://www.nccn.org/professionals/physician_gls/pdf/bone.pdf [Accessed 03.21.2020]

17. Rodríguez-Galindo C, Liu T, Krasin MJ, Wu J, Billups CA, Daw NC, Spunt SL, Rao BN, Santana VM, Navid F. Analysis of prognostic factors in ewing sarcoma family of tumors. *Cancer*, 2007, 110(2):375-384.
18. Gebhardt MC, DuBois SG. Treatment of the Ewing sarcoma family of tumors. In: Post T (Eds): *UpToDate*, Waltham, 2020, USA, 0.
19. Gaspar N, Hawkins DS, Dirksen U, Lewis IJ, Ferrari S, Le Deley MC, Kovar H, Grimer R, Whelan J, Claude L, Delattre O, Paulussen M, Picci P, Sundby HK, van den Berg H, Ladenstein R, Michon J, Hjorth L, Judson I, Luksch R, Bernstein ML, Marec-Bérard P, Brennan B, Craft AW, Womer RB, Juergens H, Oberlin O. Ewing Sarcoma: Current Management and Future Approaches Through Collaboration. *J Clin Oncol*, Sep 20, 2015, 33(27):3036-3046.
20. Kridis W, Toumi N, Chaari H, Khanfir A, Ayadi K, Keskes H, Boudawara T, Daoud J, Frikha M. et al. A Review of Ewing Sarcoma Treatment: Is it Still a Subject of Debate? *RRCT*, 2017, 12(1):19-23.
21. Granowetter L, Womer R, Devidas M, Krailo M, Wang C, Bernstein M, Marina N, Leavey P, Gebhardt M, Healey J, Shamberger RC, Goorin A, Miser J, Meyer J, Arndt CAS, Sailer S, Marcus K, Pearlman E, Dickman P, Grier HE. et al. Dose-intensified compared with standard chemotherapy for nonmetastatic Ewing sarcoma family of tumors: a Children's Oncology Group Study. *J Clin Oncol*, May 20, 2009, 27(15):2536-2541.
22. Gorlick R, Janeway KA, Adamson PC. Dose Intensification Improves the Outcome of Ewing Sarcoma. *JCO*, 2018, 36(31):3072-3073.
23. Womer RB, West DC, Krailo MD, Dickman PS, Pawel BR, Grier HE, Marcus K, Sailer S, Healey JH, Dormans JP, Weiss AR. et al. Randomized Controlled Trial of Interval-Compressed Chemotherapy for the Treatment of Localized Ewing Sarcoma: A Report From the Children's Oncology Group. *J Clin Oncol*, 2012, 30(33):4148-4154.
24. ClinicalTrials.gov, 2020, National Library of Medicine, Combination Chemotherapy With or Without Ganitumab in Treating Patients With Newly Diagnosed Metastatic Ewing Sarcoma [online]. Available at: <https://clinicaltrials.gov/ct2/show/NCT02306161> [Accessed March 26, 2020].
25. Subbiah V, Kurzrock R. Ewing's Sarcoma: Overcoming the Therapeutic Plateau. *Discov Med*, 2012-6, 13(73): 405-415.

Corresponding Author: Strimbu Codrut Vlad, "Carol Davila" University of Medicine and Pharmacy, Bucharest, Romania, e-mail: vlad.strimbu@stud.umfcd.ro