

## Aseptic Necrosis of Femoral Head - Clinical Study

RĂZVAN MARIUS VICAȘ<sup>1</sup>, FLORIAN DOREL BODOG<sup>2</sup>,  
ADINA NICOLETA CIURSAȘ<sup>1</sup>, OVIDIU FLORIN FUGARU<sup>3</sup>, FLORIN GROSU<sup>4</sup>,  
LIVIU LAZĂR<sup>5</sup>, CARMEN DELIA NISTOR CSEPPENTO<sup>5</sup>,  
GABRIELA CORINA BEIUȘANU<sup>1</sup>, CĂLIN DAVID BUZLEA<sup>1</sup>, OVIDIU ȚICĂ<sup>1</sup>,  
ILARIE BRIHAN<sup>6</sup>, MIHAELA ZDRÎNCĂ<sup>7</sup>

<sup>1</sup>Department of Morphological Disciplines, Faculty of Medicine and Pharmacy, University of Oradea, Romania

<sup>2</sup>Department of Surgery, Faculty of Medicine and Pharmacy, University of Oradea, Romania

<sup>3</sup>PhD Student, Doctoral School, University of Medicine and Pharmacy of Craiova, Romania

<sup>4</sup>Department of Histology, Victor Papilian Faculty of Medicine, Lucian Blaga University of Sibiu, Romania

<sup>5</sup>Department of Psycho-Neuroscience and Recovery, Faculty of Medicine and Pharmacy,  
University of Oradea, Romania

<sup>6</sup>Department of Dermatology, Faculty of Medicine and Pharmacy, University of Oradea, Romania

<sup>7</sup>Department of Preclinical Disciplines, Faculty of Medicine and Pharmacy, University of Oradea, Romania

**ABSTRACT:** Femoral head osteonecrosis is a disease characterized by the decrease of blood vascularization in the femoral head, which leads to death of the osteocytes, demineralization and resorption of bone spans, change of trabecular architecture, with the reduction of the bone mechanical resistance and collapse of the articular surface in the femoral head. Left untreated, the disease may have a rapid progression, leading to severe symptoms, with significant articular dysfunction, functional impotence and a serious impact on the patient's quality of life. The prevalence of the disease is ever growing all over the world, affecting mainly people in their 30s, 40s or 50s. In the present study, we analyzed a number of 76 patients with femoral head osteonecrosis with severe symptoms that required a surgical treatment. There was observed that more than ¾ of the investigated patients were males, while 81.58% were younger than 60 years old. Among the identified risk factors, smoking came first, followed by alcohol intake, obesity and chronic administration of corticosteroids. A very high percentage of patients (84.21%) were diagnosed in stages III and IV of the disease.

**KEYWORDS:** Osteonecrosis, femoral head, multifactorial process, arthroplasty, avascular necrosis.

### Introduction

Osteonecrosis of the femoral head, also called avascular necrosis, is a pathological state characterized by the decrease of subchondral bone vascularization of the femoral head, which leads to the death of osteocytes, demineralization and resorption of porous bone tissue spans, the change of trabecular architecture with the reduction of mechanic resistance of the bone and the articular surface collapse [1,2].

The ischemia state installed progressively activates osteocytes, cells that release high quantities of acid phosphatase, an enzyme involved in the resorption of bone spans [3].

Left untreated, the disease may have a rapid progression, thus leading to the femoral head collapse, one of the most severe bone changes; in this study, the disease develops through acute symptoms, sometimes intolerable ones, such as hip pain, intense articular dysfunction,

functional impotence, which seriously affects the quality of the patient's life [4,5].

Moreover, osteonecrosis of the femoral head causes significant economic and social costs, as the disease mainly affects males, aged between 30 and 50 years old, who are frequently withdrawn from the working services and require medical care [6].

The prevalence of femoral head osteonecrosis is increasing all over the world; the disease affects mainly the individuals in their 30s, 40s or 50s [7-9].

Some statistical data showed that only in the USA there are recorded about 20,000-30,000 new cases of femoral head osteonecrosis every year, the total number of patients reaching approx. 5-5.7 million patients nowadays [10,11].

More studies showed that the etiology of osteonecrosis is multi factorial, unclear and unknown [12], and in the absence of an early treatment, the natural progression of the disease is rapid, thus leading to secondary hip arthritis in a few years time [13].

In the present study, we proposed to perform a clinical study of 76 patients diagnosed with aseptic necrosis of the femoral head, who required a surgical intervention.

## Material and Methods

We made a retrospective study on 76 patients, admitted to the Orthopedics Clinic within the Emergency Clinical Hospital of Oradea between 2011 and 2015, for aseptic necrosis of the femoral head.

All the admitted patients included in the study were evaluated clinically and paraclinically, immediately after admission.

The general clinical examination tried to highlight the specific signs and symptoms of the condition that led to the admission of the patients in the orthopedics clinic, signs and symptoms of any associated conditions that may have represented risk factors for the surgical treatment, pathological history of every patient that may have been relevant for the onset and development of the present condition, as well as the performed treatments.

Paraclinically, every patient benefited from a standard x-ray of the pelvis for highlighting the changes of coxofemoral joints and especially of the bone tissue structure in the femoral head.

In the cases where pelvis x-ray did not provide sufficient data there were performed hip CT or MRA scans, in order to better highlight the extension and severity of the bone lesions, on which there was established not only the stage of the disease, but also the type of surgical intervention required.

All the patients benefited from a standard lung x-ray for establishing any active pulmonary lesions or sequelae developed after previous conditions in the past.

Also, all the patients were investigated with an EKG, in some cases being required the performance of abdominal, cardiac, doppler-color ultrasound or respiratory investigations in order to detect and evaluate any possible associated conditions.

Serological tests completed the paraclinical study in all the patients. Besides the regular biological tests (full blood count, ESR, glycemia, creatinine, urea, urine examination),

in all patients there were performed tests on blood coagulation, blood type and Rh for evaluating the operator and post-operator risks.

The data obtained were filed in Excel sheets for a statistical processing and for obtaining charts that provide descriptive synthetic aspects of our study.

The retrospective study was approved by the Ethics Comitee of the Emergency Clinical Hospital of Oradea (27433/06.11.2018).

## Results

The main symptoms presented by the patients with aseptic necrosis of femoral head in our study were the hip pain and functional impotence.

Most patients complained that the hip pain radiated towards the groin, the internal part of the thigh or within the entire lower limb.

The intensity of the pain described by the patients was variable, being more intense during morning time and especially during walking.

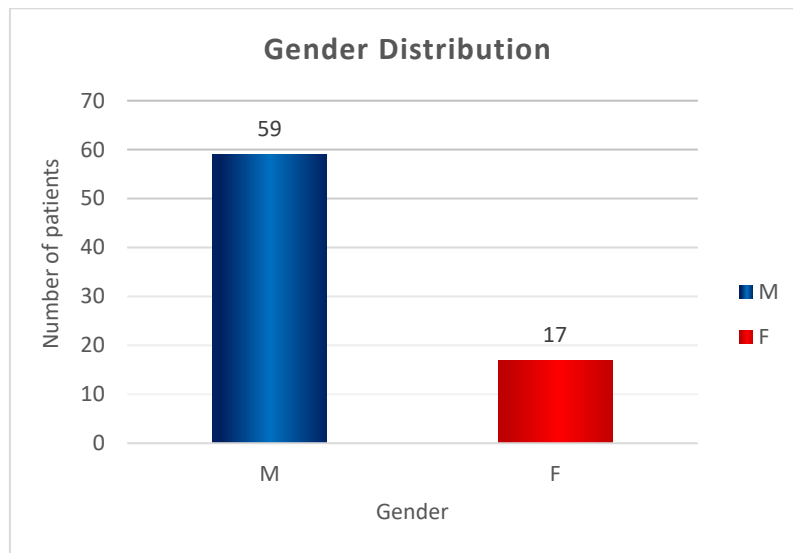
Most patients mentioned that bed rest in a horizontal position improved the pain symptoms.

Regarding the functional impotence, this was correlated with the degree of femoral head damage, thus in the cases of early osteonecrosis the flexion/extension movements of the thigh on the abdomen were possible only in relatively high limits, while the rotation movements were more reduced; in the advanced osteonecrosis cases, the limitation of movements in the hip joint were quite significant, leading up to semi-anchylosis.

Besides pain and functional impotence, some patients accused walking and orthostatism position disturbances, many of them preferring to lean on a stick or metallic crutches toggles.

Also, a high number of patients accused bilateral hip pain, as a result of a coxarthrosis on the opposite hip.

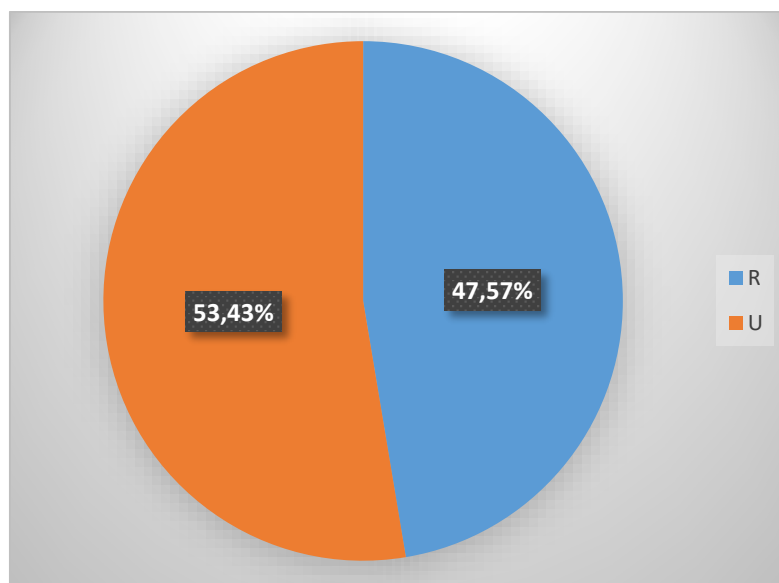
The study of the sex distribution of patients with aseptic osteonecrosis of the femoral head showed that of the 76 patients, 59 (77.63%) were males and only 17 patients (22.37%) were females (Figure 1).



**Figure 1. Gender distribution of patients with femoral head necrosis.**

The study of the patient’s living environment distribution highlighted that femoral head osteonecrosis affects individuals from the urban and rural areas almost in the same way.

Of the 76 patients, 40 (52.43%) came from the urban area and 36 (47.57%) from the rural area (Figure 2).



**Figure 2. Living environment distribution of patients: urban (U) = 40 patients (53.43%); rural (R) = 36 patients (47.57%).**

The age evaluation of our patients showed that this disease affects not only the elderly, but also young people; as it may be observed from Figure 3, femoral head osteonecrosis may affect young adults, aged under 30 years old.

Most patients in our study were aged under 60 years old; thus, of the 76 studied patients, 62 (81.58%) were aged under 60 years old, while the number of patients aged over 60 years old was only 14, representing 18.42% of all the patients.

From Figure 2 there may be observed that in the age group 50-59 years old there were recorded 28 patients, which represents 36.84%, while the number of patients with femoral head necrosis increased with age up to the age of 60 years old.

The study of the risk factors showed that most patients were smokers; as such, of the 76 patients, 23, representing 30.26% admitted that they were smokers.

The 2nd place regarding the incidence of risk factors was represented by alcohol intake.

Thus, 12 patients, representing 15.79% admitted that they were alcohol consumers.

Regarding this risk factor, we consider that the data provided by the patients do not correspond to reality, most often the patients being unable or unwilling to offer a clear quantity of the alcohol they consumed daily or monthly.

On the 3rd place of risk factors in our group we identified obesity.

This was identified in 11 patients, representing 14.47%.

On the 4th and 5th place among the risk factors we identified chronic treatment with corticosteroids (in 6 patients, representing 7.89%) and hip traumas also in 6 patients.

A number of 5 patients, representing 6.58%, presented various blood coagulation conditions (Figure 4).

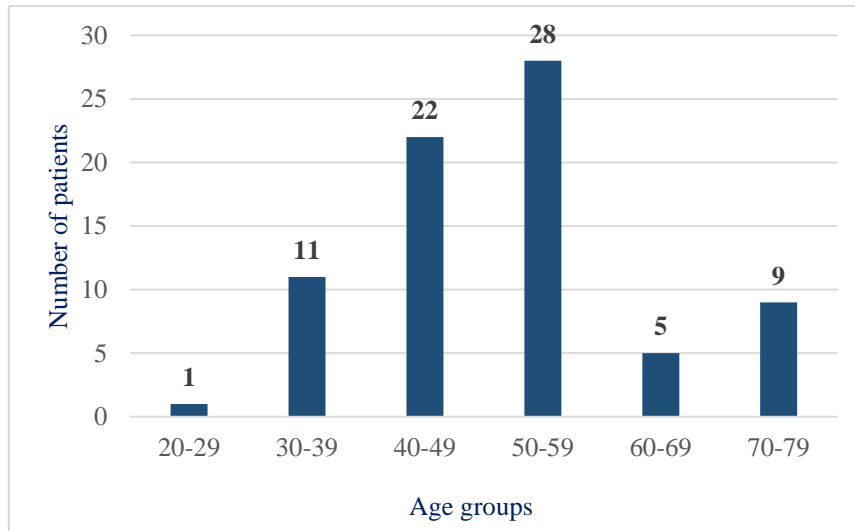


Figure 3. Age distribution of patients with femoral head necrosis

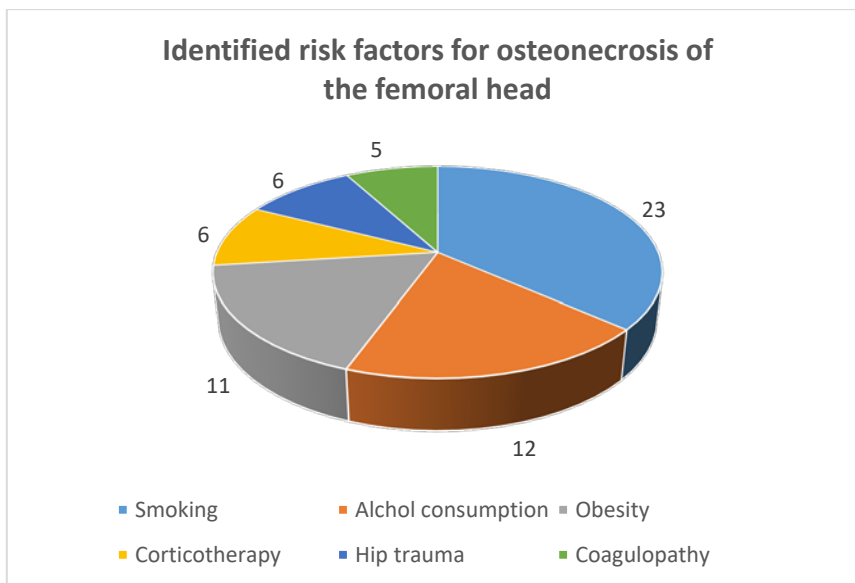


Figure 4. Risk factors involved in the etiopathology of femoral head necrosis in the studied group.

We should mention the fact that some patients presented 2 or even 3 risk factors, while in others we did not identify any risk factor,

which made us consider those cases as idiopathic.

Regarding the stage of the disease, in our study, we took into consideration the clinical

signs and symptoms, the functional impotence degree and the bone tissue changes in the femoral head identified on the x-ray, CT or MRA images.

In our study, only 12 patients (15.79%) were diagnosed in stages I and II, the rest of them

being diagnosed in advanced stages of the disease.

Thus, 23 patients, representing 30.26% were diagnosed in stage III, while 41 patients, representing 53.95% were diagnosed in stage IV of the disease (Figure 5).

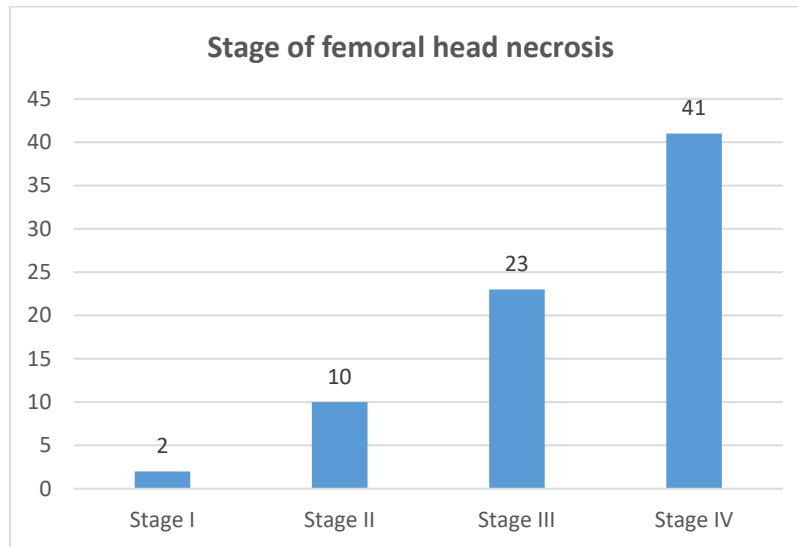


Figure 5. Stages of femoral head necrosis in the studied group.

All the patients included in the study benefited from surgical treatment; as it may be observed in Figure 6, according to the particularities of every patient, there were performed three types of surgical interventions: core decompression (CD) in 15 cases (19.74%), cementless total hip arthroplasty (cementless THA), 44 cases (57.89%) and cemented total hip arthroplasty (cemented THA) in 17 cases (22.37%).

The core decompression were performed in the initial stages of the disease, in young persons, in order to stimulate a revascularization of the necrosis area in the femoral head; cementless total hip arthroplasty was performed in advanced stages of the disease, in individuals up to 65 years old and with a good biological status, while cemented total hip arthroplasty was performed in patients aged over 65 years old, with a poor bone quality.

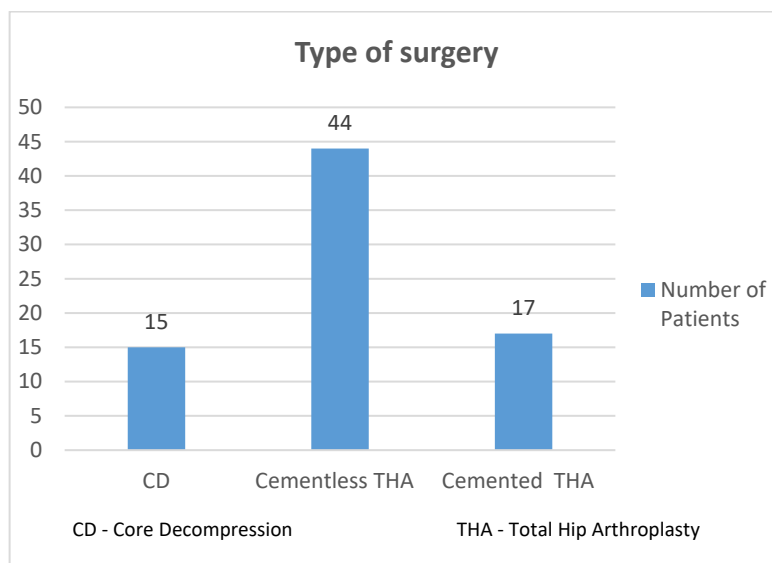


Figure 6. Types of surgical interventions practiced on the patients in the studied group.

## Discussion

Aseptic osteonecrosis is a disease that may progress for a long time without any significant clinical symptoms, which makes most patients to be diagnosed in the late stages of this disease [14,15].

As shown by numerous studies, the disease mainly affects males aged between 30 and 50 years old [6,16-19].

Our study showed that the disease mainly affects men and the onset may be even before the age of 30 years old.

Aseptic osteonecrosis of the femoral head is a multifactorial disease, in its etiopathology being identified metabolic and local factors that affect the blood supply of the femoral head and neck [20].

Of the genetic factors, the most studied gene is MTHFR that codifies the formation of the methylenetetrahydrofolate enzyme reductase involved in the homocysteine remethylation of methionine [21].

The MTHFR mutations observed in some Asian populations diagnosed with femoral head necrosis may affect the metabolism and the levels of homocysteine.

There was shown that high levels of homocysteine negatively affect bone resistance [22], while high plasma concentrations of its metabolites are correlated with a higher risk of bone fracture [23].

Moreover, there was reported that high levels of homocysteine and its associated metabolite, S-adenosylhomocysteine (SAH), cause structural changes of the bone, characterized by a high trabecular destruction and a low trabecular thickness [24,25].

Of the changeable factors associated to femoral head osteonecrosis we identified smoking, alcohol intake, chronic administration of corticosteroids, obesity, hip traumas and blood coagulation disorders.

Smoking was identified in 23 patients, representing 30.26% of our group.

We consider smoking to be an essential factor involved in the osteonecrosis etiopathology, as it may increase tissue hypoxia, including in the bone tissue.

Moreover, there was shown that smoking inhibits osteogenesis and fracture healing, therefore it is not surprising the fact that it represents a risk factor for osteonecrosis.

There is a high risk for present smokers to develop femoral head necrosis, still it should be taken into consideration that smoking has a

cumulative effect highlighted in patients who smoked for more than 20 years, more than one pack of cigarettes a day.

The physiopathological effects are still unclear, but there exist vascular changes that lead to the decrease of local blood flow and the decrease of hematogenous bone marrow activity [26,27].

Chronic alcohol intake represents another environmental factor involved in the etiopathology of femoral head necrosis. In our study we identified 12 patients who consumed alcohol, representing 15.79%.

Although their number seems small, we believe that their real number is a lot higher, as some patients did not declare themselves as alcohol consumers, and there was no paraclinical method of identifying the ones who consumed alcohol.

The studies performed so far showed that there is a higher risk of osteonecrosis in occasional or frequent alcohol consumption, in comparison to those who do not consume alcohol at all [28,29].

Also, there seems to be a connection between the severity of the lesion of femoral head osteonecrosis and the quantity of alcohol ingested, as well as the duration of the consumption.

Although the real incidence of osteonecrosis is low, in alcoholic patients there was reported an incidence up to 29.2% [30].

Matsuo et al (1988) found a high risk in regular alcohol consumers (48ml alcohol daily), in comparison to patients who did not consume alcohol [31].

Another factor involved in the etiopathology of femoral head necrosis is represented by the treatment with anti-inflammatory drugs, like corticosteroids.

The risk for osteonecrosis associated with corticosteroids is quite high in patients who suffered a renal transplant, in those who suffer from major collagen disorders (erythematous lupus, scleroderma, rheumatoid polyarthritis) due to the mineralization defects and structural weakness of the bone induced by the treatment.

In our study, only 6 patients, representing 7.89%, declared having been subjected to chronic corticotherapy.

A meta-analysis of 22 studies on osteonecrosis associated to the chronic treatment with steroids highlighted a 4.6 higher increase of osteonecrosis progression rate for every 10mg/day of increasing the average daily dose [32].

The physiopathological mechanisms through which corticosteroids cause osteonecrosis are multiple ones and insufficiently known.

The activity level and number of mesenchymal cells, both in the hematopoietic and stromal compartments of the bone marrow, proved to be quite low in patients with femoral head osteonecrosis induced by steroids.

Prolonged treatment with steroids also stimulates the differentiation of pluripotent stromal cells of the bone marrow into adipocytes [33].

Adipogenesis induced by steroids in the bone stem cells and the systemic changes of the lipid metabolism are major contributors to the osteoporosis and osteonecrosis caused by steroids [34], while the hypertrophy of adipose cells may determine a high intraosseous pressure, followed by a bone ischemia and osteonecrosis [35].

Coagulation disorders (coagulopathies) represent another risk factor involved in femoral head necrosis.

In our study, coagulation disorders were identified only in 5 patients.

The emboli and thrombi were found both in the arterioles and in the venules of osteonecrotic tissue, in some animal experimental models. Individuals with an inherited coagulation disorder may have a higher risk of developing femoral head osteonecrosis, in comparison to normal individuals, through thrombotic occlusion of microcirculation in the femoral head and a low capacity of hypofibrinolysis (a low capacity of intravascular thrombi lysis) [36].

Another particular aspect of our study was that most patients who were admitted in our clinic were diagnosed in late stages of the disease.

Thus, of the 76 patients, 64 (84.21%) were diagnosed in stages III and IV.

This aspect may be due to the medical education of the population, to a medical system that cannot diagnose the disease in its early stages or to the material situation.

Regarding the treatment applied to our patients, most of them benefited from cementless total hip arthroplasty (cementless THA), 44 cases (57.89%), 17 patients (22.37%) benefited from cemented total hip arthroplasty (cemented THA), while for 15 patients (19.74%), there were performed core decompression in the femoral head for a revascularization of the osteonecrosis area.

At present, in the treatment of femoral head aseptic necrosis there are used two major methods:

- non-surgical methods;
- surgical methods.

Non-surgical methods apply in the early stages of the disease, most often in asymptomatic osteonecroses, most often being used for preventing the disease progression [37,38].

Reducing body weight, controlling obesity and lipidic metabolism changes represent the most important indications for stopping disease progression [39].

Surgical treatment mainly applies in the advanced stages of femoral head necrosis; femoral head core decompression has the purpose of reducing the interosseous pressure, stimulating angiogenesis and osteogenesis, thus reducing the pain felt by the patient, heaving the best outcomes when used in the earliest, pre-collapse stages of the disease with small lesions.

A study performed by MA et al (1996) showed that the rate of success for this surgery was about 70% after 5 years, without any other additional surgical intervention [40].

Moreover, it seems that drillings associated with bone grafting lead to the improvement of the processes of bone tissue formation and increase of bone resistance [41].

In the case of damaged articulations, it is required total hip arthroplasty.

Still, there is no consensual decision regarding the use of total hip arthroplasty in patients with sickle cell disease, erythematosus lupus, prolonged intake of corticosteroids, alcohol abuse or renal transplant [42].

## Conclusions

All the patients included in the study presented intense hip pain and functional impotence, which required their admission to an orthopedics clinic and the performance of a surgical treatment.

Of the 76 patients, 59 (77.63%) were males and only 17 patients (22.37%) were females.

The study of patient distribution according to the living environment highlighted that femoral head osteonecrosis affects both people from the urban area and the rural one, in the same way.

Regarding age, there was observed that the disease affects not only elderly people, but also young people, as well, even under 30 years old.

In our study, most patients (62 representing 81.58%) were aged under 60 years old; of these,

in the age group 50-59 years old, there were recorded 28 patients, representing 36.84%.

Most patients (64, representing 84.21%) were diagnosed in stages III and IV of the disease.

Of the identified risk factors, smoking came on the first place, followed by alcohol intake, obesity and chronic administration of corticosteroids.

### Conflict of interests

None to declare.

### References

- Gou WL, Lu Q, Wang X, Wang Y, Peng J, Lu SB. Key pathway to prevent the collapse of femoral head in osteonecrosis. *Eur Rev Med Pharmacol Sci*, 2015, 19(15):2766-2774.
- Petek D, Hannouche D, Suva D. Osteonecrosis of the femoral head: pathophysiology and current concepts of treatment. *EFORT Open Rev*, 2019, 4(3):85-97.
- Li W, Sakai T, Nishii T, Nakamura N, Takao M, Yoshikawa H, Sugano N. Distribution of TRAP-positive cells and expression of HIF-1 $\alpha$ , VEGF, and FGF-2 in the reparative reaction in patients with osteonecrosis of the femoral head. *J Orthop Res*, 2009, 27(5):694-700.
- Wang C, Peng J, Lu S. Summary of the various treatments for osteonecrosis of the femoral head by mechanism: A review. *Exp Ther Med*, 2014, 8(3):700-706.
- Chen SB, Hu H, Gao YS, He HY, Jin DX, Zhang CQ. Prevalence of clinical anxiety, clinical depression and associated risk factors in Chinese young and middle-aged patients with osteonecrosis of the femoral head. *PLoS One*, 2015, 10(3):e0120234.
- Arbab D, König DP. Atraumatic Femoral Head Necrosis in Adults. *Dtsch Arztebl Int*, 2016, 113(3):31-38.
- Kang JS, Park S, Song JH, Jung YY, Cho MR, Rhyu KH. Prevalence of osteonecrosis of the femoral head: A nationwide epidemiologic analysis in Korea. *J Arthroplasty* 2009, 24(8):1178-1183.
- Cooper C, Steinbuch M, Stevenson R, Miday R, Watts NB. The epidemiology of osteonecrosis: findings from the GPRD and THIN databases in the UK. *Osteoporos Int*, 2010, 21(4):569-577.
- Fukushima W, Fujioka M, Kubo T, Tamakoshi A, Nagai M, Hirota Y. Nationwide epidemiologic survey of idiopathic osteonecrosis of the femoral head. *Clin Orthop Relat Res*, 2010, 468(10):2715-2724.
- Aldridge JM 3rd, Urbaniak JR. Vascularized fibular grafting for osteonecrosis of the femoral head with unusual indications. *Clin Orthop Relat Res*, 2008, 466(5):1117-1124.
- Wang C, Meng H, Wang Y, Zhao B, Zhao C, Sun W, Zhu Y, Han B, Yuan X, Liu R, Wang X, Wang A, Guo Q, Peng J, Lu S. Analysis of early stage osteonecrosis of the human femoral head and the mechanism of femoral head collapse. *Int J Biol Sci*, 2018, 14(2):156-164.
- Scaglione M, Fabbri L, Celli F, Casella F, Guido G. Hip replacement in femoral head osteonecrosis: current concepts. *Clin Cases Miner Bone Metab*, 2015, 12(Suppl 1):51-54.
- Kang JS, Moon KH, Kwon DG, Shin BK, Woo MS. The natural history of asymptomatic osteonecrosis of the femoral head. *Int Orthop*, 2013, 37(3):379-384.
- Fondi C, Franchi A. Definition of bone necrosis by the pathologist. *Clin Cases Miner Bone Metab*, 2007, 4(1):21-26.
- Manenti G, Altobelli S, Pugliese L, Tarantino U. The role of imaging in diagnosis and management of femoral head avascular necrosis. *Clin Cases Miner Bone Metab*, 2015, 12(Suppl 1):31-38.
- Lieberman JR, Berry DJ, Mont MA, Aaron RK, Callaghan JJ, Rajadhyaksha AD, Urbaniak JR. Osteonecrosis of the hip: management in the 21st century. *Instr Course Lect*. 2003;52:337-355.
- Rajpura A, Wright AC, Board TN. Medical management of osteonecrosis of the hip: a review. *Hip Int*, 2011, 21(4):385-392.
- Kuroda Y, Matsuda S, Akiyama H. Joint-preserving regenerative therapy for patients with early-stage osteonecrosis of the femoral head. *Inflamm Regen*, 2016, 36:4.
- Li B, Lei P, Liu H, Tian X, Wen T, Hu R, Hu Y. Clinical value of 3D printing guide plate in core decompression plus porous bioceramics rod placement for the treatment of early osteonecrosis of the femoral head. *J Orthop Surg Res*, 2018, 13(1):130.
- Mont MA, Hungerford DS. Non-traumatic avascular necrosis of the femoral head. *J Bone Joint Surg Am*, 1995, 77(3):459-474.
- Kutlar A, Kutlar F, Turker I, Tural C. The methylene tetrahydrofolate reductase (C677T) mutation as a potential risk factor for avascular necrosis in sickle cell disease. *Hemoglobin*, 2001, 25(2):213-217.
- Herrmann M, Tami A, Wildemann B, Wolny M, Wagner A, Schorr H, Taban-Shomal O, Umanskaya N, Ross S, Garcia P, Hübner U, Herrmann W. Hyperhomocysteinemia induces a tissue specific accumulation of homocysteine in bone by collagen binding and adversely affects bone. *Bone*, 2009, 44(3):467-475.
- Yang J, Hu X, Zhang Q, Cao H, Wang J, Liu B. Homocysteine level and risk of fracture: A meta-analysis and systematic review. *Bone*, 2012, 51(3):376-382.
- Holstein JH, Herrmann M, Splett C, Herrmann W, Garcia P, Histing T, Klein M, Kurz K, Siebel T, Pohlemann T, Menger MD. High bone concentrations of homocysteine are associated with altered bone morphology in humans. *Br J Nutr*, 2011, 106(3):378-382.
- Narayanan A, Khanchandani P, Borkar RM, Ambati CR, Bhoskar RN, Ragampeta S, Gannon F, Mysorekar V, Karanam B, V SM, Sivaramakrishnan V. Avascular Necrosis of Femoral Head: A Metabolomic, Biophysical, Biochemical, Electron Microscopic and Histopathological Characterization. *Sci Rep*, 2017, 7(1):10721.
- Takahashi S, Fukushima W, Kubo T, Iwamoto Y, Hirota Y, Nakamura H. Pronounced risk of nontraumatic osteonecrosis of the femoral head among cigarette smokers who have never used oral corticosteroids: a multicenter case-control study in Japan. *J Orthop Sci*, 2012, 17(6):730-736.



27. Wen Z, Lin Z, Yan W, Zhang J. Influence of cigarette smoking on osteonecrosis of the femoral head (ONFH): a systematic review and meta-analysis. *Hip Int*, 2017, 27(5):425-435.
28. Lavernia CJ, Villa JM, Contreras JS. Alcohol use in elective total hip arthroplasty: risk or benefit? *Clin Orthop*, 2013, 471(2):504.
29. Ponzio DY, Pitta M, Carroll KM, Alexiades M. Hip arthroplasty for osteonecrosis of the femoral head secondary to alcohol abuse. *Arthroplast Today*, 2018, 5(2):172-175.
30. Yuan B, Taunton MJ, Trousdale RT. Total hip arthroplasty for alcoholic osteonecrosis of the femoral head. *Orthopedics*, 2009, 32(6):400.
31. Matsuo K, Hirohata T, Sugioka Y, Ikeda M, Fukuda A. Influence of alcohol intake, cigarette smoking, and occupational status on idiopathic osteonecrosis of the femoral head. *Clin Orthop Relat Res*, 1988, 234:115-123.
32. Felson DT, Anderson JJ. A cross study evaluation of association between steroid dose and bolus steroids and avascular necrosis of bone. *Lancet*, 1987, 1(8538):902-906.
33. Cui Q, Wang GJ, Balain G. Steroid induced adipogenesis in a pluripotential cell line from bone marrow. *J Bone Joint Surg*, 1997, 79-A:1054-1063.
34. Cui Q, Wang GJ, Su CC, Balain G. The Otto Aufranc Award. Lovastatin prevents steroid induced adipogenesis and osteonecrosis. *Clin Orthop Relat Res*, 1997, (344):8-19.
35. Wang GJ, Cui Q, Balain G. The Nicolas Andry Award: the pathogenesis and prevention of steroid induced osteonecrosis. *Clin Orthop*, 2000, 370:295-310.
36. Jones LC, Hungerford DS. Osteonecrosis: etiology, diagnosis, and treatment. *Curr Opin Rheumatol*, 2004, 16(4):443-449.
37. Kaushik AP, Das A, Cui Q. Osteonecrosis of the femoral head: An update in year 2012. *World J Orthop*, 2012, 18;3(5):49-57.
38. Cao H, Guan H, Lai Y, Qin L, Wang X. Review of various treatment options and potential therapies for osteonecrosis of the femoral head. *J Orthop Translat*, 2015, 4:57-70.
39. Pritchett JW. Statin therapy decreases the risk of osteonecrosis in patients receiving steroids. *Clin. Orthop. Relat. Res*, 2001, (386):173-178.
40. Mont MA, Carbone JJ, Fairbank AC. Core decompression versus nonoperative management for osteonecrosis of the hip. *Clin Orthop Relat Res*, 1996, 324:169-178.
41. Pater AN, Mittal S, Vina RF, Benetti F, Trehan N. Long term follow-up of coronary artery bypass grafting with autologous bone marrow cell therapy. *Cytotherapy*, 2014, 16:S39.
42. Parsons SJ, Steele N. Osteonecrosis of the femoral head: Part 2. Options for treatment. *Curr Orthopaed*, 2008, 22:349-158.

---

*Corresponding Author: Adina Nicoleta Ciursas, Department of Morphological Disciplines, Faculty of Medicine and Pharmacy, University of Oradea, 1st December Square 10, 410073 Oradea, Romania, e-mail: adina.ciursas@gmail.com*